



X0123882

United Nations International Criminal Tribunal for
the former Yugoslavia

AUTOPSY REPORT
RAVNICE GRAVE SITE

Case No: RV02 / 164B

Autopsy Date: 08-Aug-01

Mortuary: Visoko

Summary:

Fully skeletonized human remains with clothing and some other personal belongings. Most parts of the skull and some long and small bones of the skeleton were missing. In addition to the bones that constituted the main skeleton some commingled bones also were found.

The cause of the skull fracture cannot be determined due to the absence of many bones. However, the injury found in the lower limbs are fatal and apart from disabling the deceased they could have killed him in the ordinary course of nature, if he had not died of any other traumatic cause, which cannot be determined due to the absence of the skull, other bones and soft tissues.

Anthropologically this person was probably male, aged between 20 and 55 years with an estimated height of 179.4+/- 7.7cm.

The injuries found in the lower limbs are consistent with high velocity bullet injuries.

Cause of Death:

It is my determination that the cause of death in case number **RV02 / 164B** was:

Multiple high velocity bullet injuries

This formal report is based upon the autopsy report that I prepared at the time of my examination. Both reports truly and accurately reflect my findings.

Signed: 

Dr A. Samarasekera, MD, MBBS, DLM, DMJ, Dip.FM

Date: 13-Aug-01

A. General Description of Remains:

Fully skeletonized human remains of an adult with some clothing and personal belongings. There were commingled bones which were separated from the main skeleton and taken into a separate bag. Only one piece of skull bone and the mandible were found. All bones were dry.

B. Clothing and Other Items:

Clothing:

- Trouser with a black belt
- A sock
- A shoe
- Short sleeved shirt

Blindfolds: No

Ligatures: No

Other Items:

- Wristwatch and a watch strap (separate)
- Cigarette case

C. Identifying Features:

Sex

From examination of soft tissues: Not possible

From anthropology details: Possible male

Age Range

From anthropology data: 20 - 55 years

Build Not possible

Height (cm)

From estimation of intact body: Not possible

From anthropology data: 179.4 +/- 7.7 cm

Hair

Head hair: Not possible

Beard: Not possible

Moustache: Not possible

Teeth

General description: No teeth due to absent skull bones in upper jaw. Few teeth in lower jaw.

Tattoos: Not possible

Scars: Not possible

Other Features: None

D. Body Parts Missing: See Anthropology Report Anthropologist L. Leppo

E. Injuries:

Findings on fluoroscopy

Radiographer E. Canniff

• Small opaque fragments

Main injuries described

Head & Neck

1 Fracture of the skull. Only one piece of bone of left temporal area and the mandible was found. All other parts of the skull were missing.

Probably ante-mortem	Probably post-mortem	Cannot tell
<input type="checkbox"/>	<input type="checkbox"/>	<input checked="" type="checkbox"/>

Trunk

2 Fracture of inner end of the left collar bone and the left first rib.

Probably ante-mortem	Probably post-mortem	Cannot tell
<input type="checkbox"/>	<input type="checkbox"/>	<input checked="" type="checkbox"/>

Legs

- | | | Probably
ante-mortem | Probably
post-mortem | Cannot
tell |
|---|---|-------------------------------------|--------------------------|--------------------------|
| 3 | Burst-out type fracture of the right tibia in its upper third with bone deficit area of 3 x 2cm in the medial surface. The fracture continues along the shaft of the tibia towards the knee joint. Burst-out type fracture in the lateral articular surface and the lateral condyle of the right femur with, 6 x 5cm area of bone deficiency. The fracture pattern is consistent with penetrating high velocity bullet injury with probable entry wound in the medial surface of the tibia and exit wound in outer aspect of knee joint. Corresponding area in the fibula bone is also fractured. | <input checked="" type="checkbox"/> | <input type="checkbox"/> | <input type="checkbox"/> |
| 4 | Burst-out type fracture of the shaft of the left tibia. Upon reconstruction a bone deficient area of 3 x 2cm was found in the medial aspect of the upper third of the tibia with radiating fractures from its margin. The wound track continues upwards with another bone deficient area in the lateral aspect of the tibia close to the knee. The fibula bone is also fractured. The injury is consistent with high velocity penetrating bullet injury with probable entry wound in the medial aspect and exit wound in the outer lateral aspect of the leg. | <input checked="" type="checkbox"/> | <input type="checkbox"/> | <input type="checkbox"/> |

F. Internal Tissues:

None

G. Samples and Other Items Recovered:

Soco J. McCartney

Bullets / Shrapnel

None

Anthropology

None

DNA

- right femur
- tooth (no.34)

Other

None



United Nations
International Criminal Tribunal
for former Yugoslavia

CASE NO:

RV 02

164 B

GRAVE SITE: ~~RV~~ RV - 02
MORTUARY: Visoko
DATE: 8/8/2001
PATHOLOGIST: SAM
ANTHROPOLOGIST: ~~Sam~~ L.L.

AUTOPSY REPORT

A. GENERAL DESCRIPTION OF REMAINS

fully skeletonized human remains of an adult with some clothing and personal belongings. There were commingled bones which were separated from the main skeleton and taken into a separate bag bearing number RV02 - - - B. ~~There is~~ only one piece of skull bone ~~found~~ ^{was} found. ~~found~~ All bones are dry.

CASE NO: RV 02
164 B

C. IDENTIFYING FEATURES

SEX (from external examination) M F not possible

BUILD not possible

HEIGHT (only if intact body) NP .

HAIR (colour, length, distribution)

Head not possible

Facial none obvious not possible

Body (if appropriate).....

TEETH (general description) No teeth due to not possible

absent small sockets in upper jaws. retained for dentist

few teeth in lower jaw

TATTOOS (general description and site)..... none obvious

not possible

SCARS..... none obvious

not possible

ANY OTHER FEATURES

RV 02
164 B

CASE NO:

B. CLOTHING (after washing)

DISPOSAL

KEPT BODY BAG

trousers with a black belt

x

a socks

x

a shoe

x

~~trousers~~

x

short sleeved shirt

x

OTHER ITEMS

DISPOSAL

KEPT BODY BAG

1. wrist watch and a watch strap (separate)

x

2. cigarette case

x

Rv 02
164 B

CASE NO:

E. INJURIES

(i) FLUOROSCOPY FINDINGS

RADIOGRAPHER E.C.

PRINT TAKEN
YES NUMBER

Small, opaque fragments

✓

(ii) MAIN INJURIES DESCRIBED (Please number and also use diagrams)

HEAD AND NECK

Probably Ante Mortem Probably Post Mortem Can't Tell

① Fracture of the skull. Only one piece of bone of ^{left} ~~right~~ ^{temporal} ~~occipital~~ area ~~is present~~ and the mandible are present found. All other parts of skull is missing.

RV 02
164 B

CASE NO:

E. MAIN INJURIES (continued)

Probably ante mortem	Probably post mortem	Can't tell
----------------------	----------------------	------------

TRUNK

② Fracture of inner end of left collar bone and the left first ribs

		X
--	--	---

LIMBS

③ Burst-out type fracture of the right tibia in its upper third medial end base of 3x2 cm deflected area in the medial surface fracture continues along the shaft of the tibia towards the knee joint. Burst-out type fracture

in the lateral articular surface and the lateral epicondyle of the right femur 6x5 cm area of bone deflection. The fracture pattern is penetrating high velocity ball injury with entry wound in the medial surface of the tibia and exit wound in outer aspect of knee joint. Corresponding area in the fibula base is also fractured.

R102
164B

CASE NO:

E. INJURIES (continued) - as required

	Probably ante mortem	Probably post mortem	Can't tell
<p>④ Burst-out type fracture of the shaft of the left tibia. Upon reconstruction a bone deficient area of 3x2 cm ^{is found} in the medial aspect of upper third of the tibia and exit ^{radiating} fracture lines from its margin. The wound tract ^{wound tract} is continuing upwards and a to another bone deficient area in the lateral aspect of the tibia ^{close} close to the knee. The fibula bone is also fractured. The injury is consistent with high velocity penetrating bullet injury with probable entry wound in the medial aspect and exit ^{wound} in the outer aspect lateral aspect of the leg.</p>			

F. INTERNAL TISSUES (if not covered under injuries)

No soft tissues remaining

RV02
164B

CASE NO:

Amanda

G. PHOTOGRAPHS TAKEN

Photographer

Injuries to both lower limbs -

~~*Amanda*~~

H. SAMPLES AND ITEMS RETAINED

(other than clothing and possessions)

SOCO

So.

BULLETS/SHRAPNEL (description and site)

Nil

Refers fluoroscopy
print number

Exhibit
No.

ANTHROPOLOGY

DNA

R1 finger

OTHER

Toon

I. SUMMARY OF FINDINGS AND CONCLUSIONS

fully skeletonized human remains of size clothing and some other personal belongings. Most parts of the skull and ~~other~~ ^{some} long and small bones of the skeleton were missing. In addition to the bones that constituted the main skeleton some commingled bones also were found.

The causation of skull fracture cannot be determined due to absence of many bones. However the injuries found in the lower limbs are fatal and apart from disabling the deceased may well have killed him in the ordinary course of nature if he had not died of any other traumatic cause which cannot be determined due to absence of skull, other bones and soft tissue.

Anthropologically determined sex is probably male, age is 20-55 yrs and the stature is 179.4 ± 7.7 cm.

The injuries found in the lower limbs are consistent with high velocity bullet injuries.

(continue over as required)

CAUSE OF DEATH

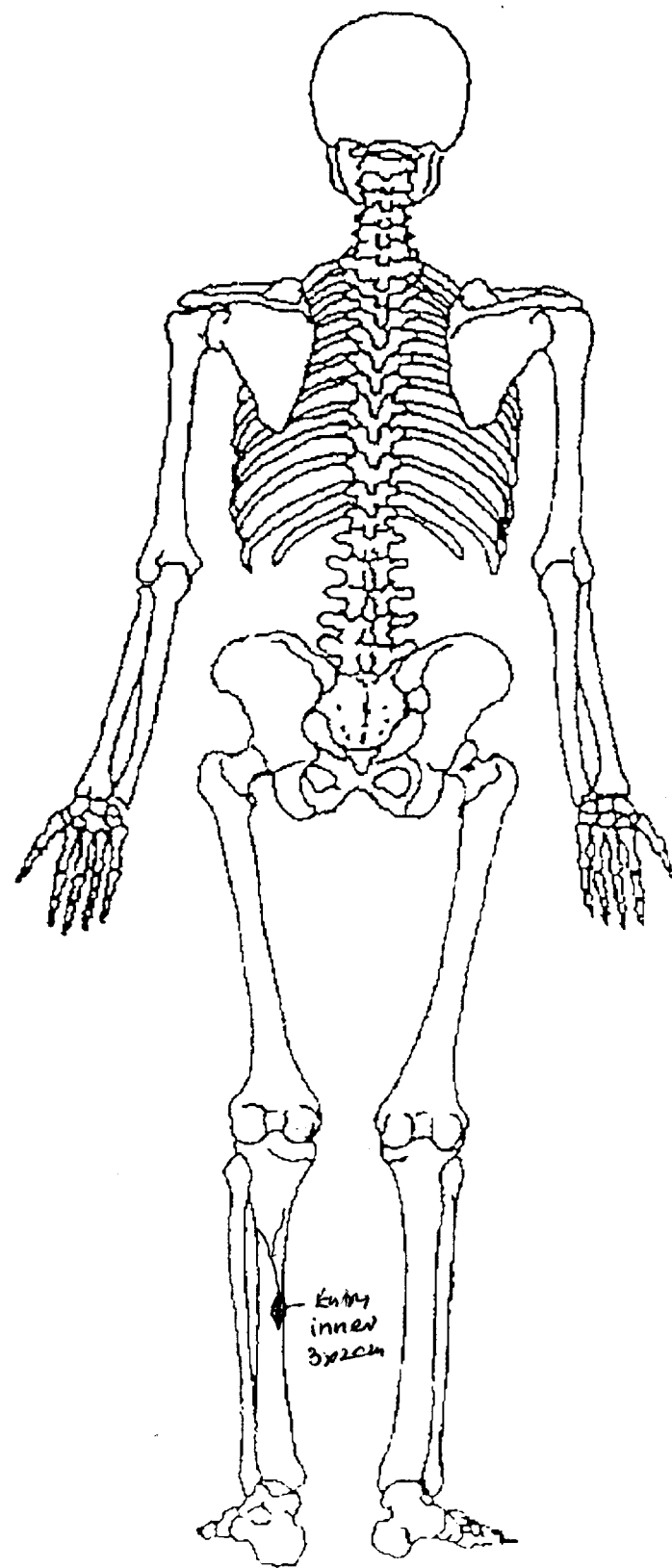
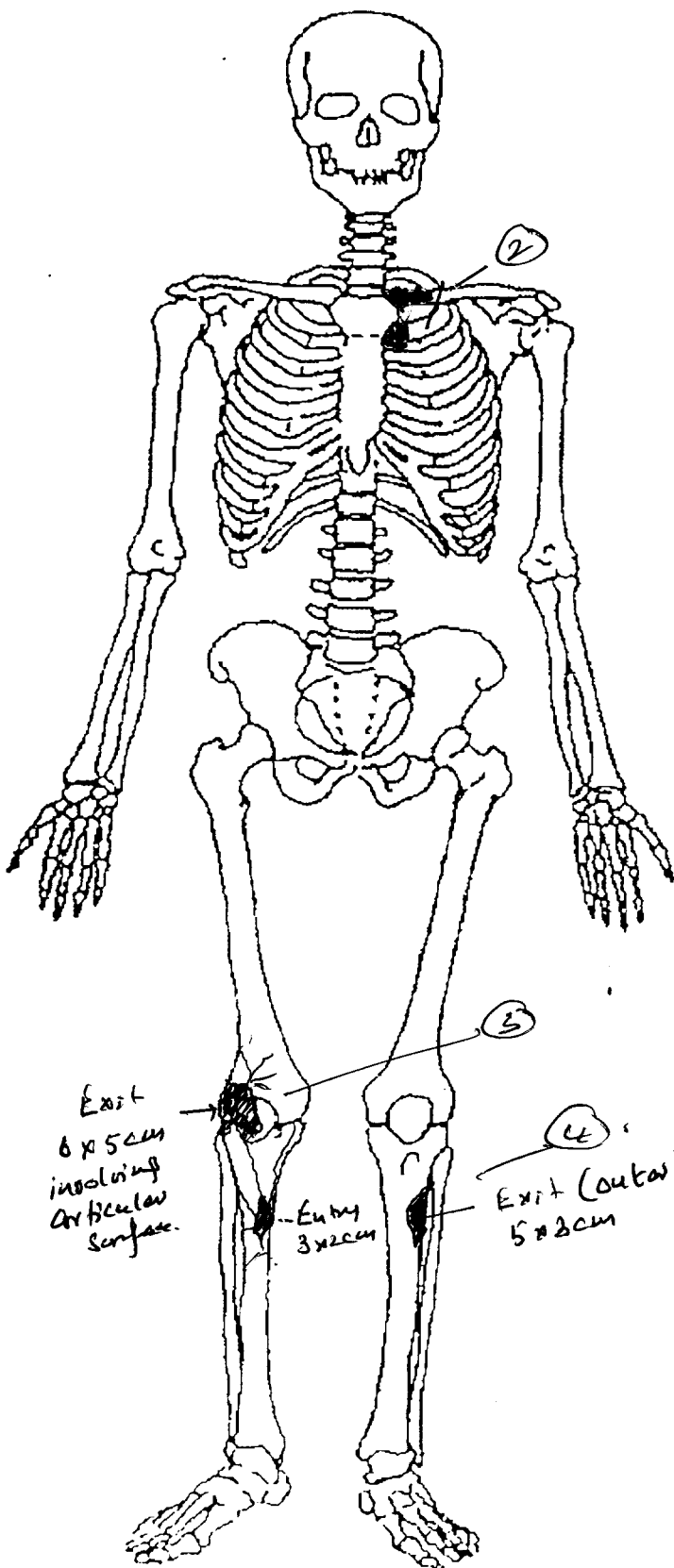
It is my determination that the cause of death in case no: RV02 164B was Multiple high velocity bullet injuries. ~~to the leg.~~

SIGNED:

NAME: DR. ANANDA SAMARASEKERA

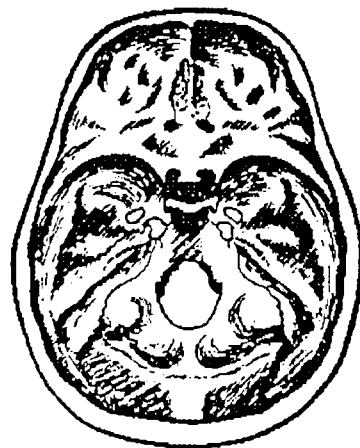
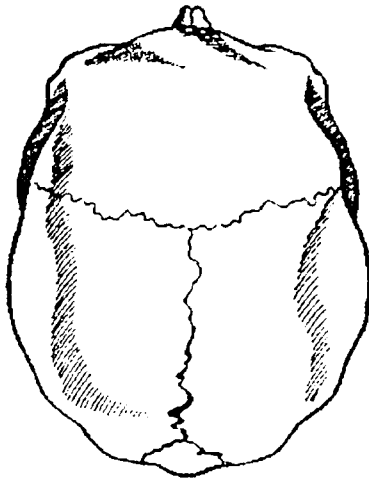
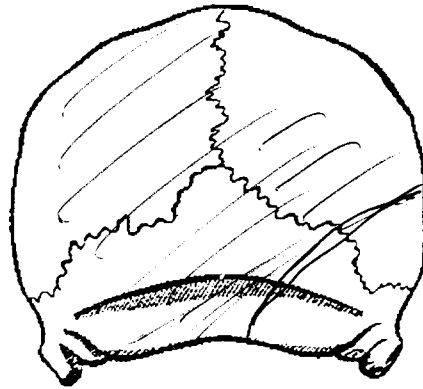
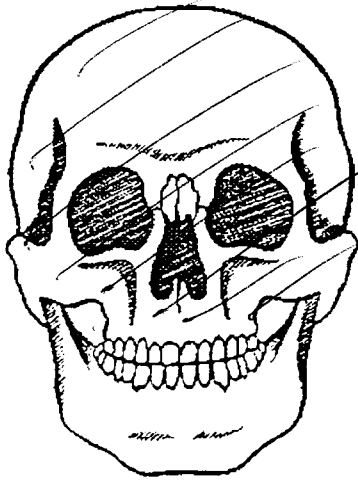
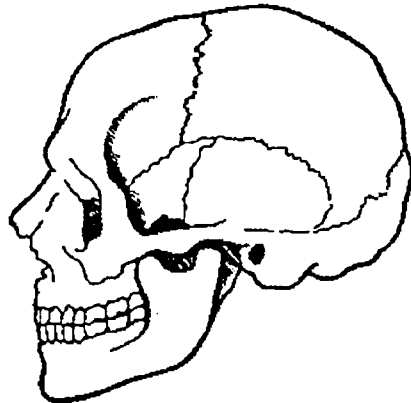
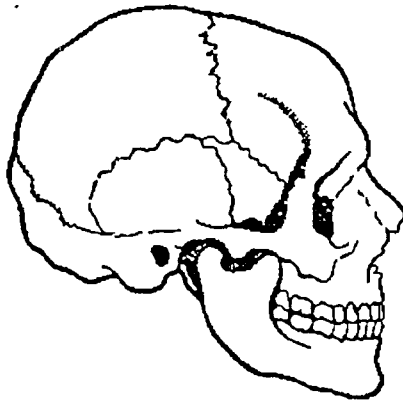
QUALIFICATIONS: MD, MBBS, DLM, DMS, Dip F.M.

DATE: 08/08/2001



CASE NO:

RV 02
164 B



RV 02
164B

CASE NO:

D. ANTHROPOLOGY DETAILS *JF*

PROBABLY

(i) SEX: MALE/FEMALE/INDETERMINATE (circle one)

Os coxae:

- Subpubic concavity..... (1/0/NO)
- Ischiopubic ramus ridge..... (1/0/NO)
- Greater Sciatic notch..... (1/2/3/4/5/NO)
- Ventral arc..... (1/0/NO)
- Preauricular sulcus..... (1/2/3/4/NO)

Cranium:

- Nuchal crest..... (1/2/3/4/5/NO)
- Mastoid process..... (1/2/3/4/5/NO)
- Supraorbital margin..... (1/2/3/4/5/NO)
- Prominence of Glabella..... (1/2/3/4/5/NO)
- Mental eminence..... (1/2/3/4/5/NO)

(ii) AGE RANGE ADULTS 20-55

	Phase	Range	Mean
Suchey Brookes	<u>NR</u>		
Ischan-Loth	<u>NO</u>		
<u>LAMENDIN</u>	<u>43</u>	<u>22.2-53.2</u>	<u>37.7</u>

(iii) AGE RANGE SUBADULTS

Dental Calcification

Tooth	Phase
.....
.....
.....
.....
.....
.....

Union of Epiphyses

Epiphyses	Fusion
.....
.....
.....
.....
.....
.....

(iv) STATURE (cm) 179.4 +/- 7.7

- Max Length Femur (R/L) 491
- Max Length Tibia (R/L)
- Max Length Fibula (R/L)
- Other long bone (R/L)
- Formula Used

RV 02
164B

CASE NO:

(v) SKELETAL INVENTORY *JJ*

Element	Present	Absent	#
CRANIUM		✓	
Frontal		✓	
R Parietal		✓	
L Parietal		✓	
Occipital		✓	
R Temporal		✓	
L Temporal	✓		
R Maxilla		✓	
L Maxilla		✓	
MANDIBLE	✓		

Element	Present	Absent	#
R Clavicle	✓		
L Clavicle	✓		
R Scapula		✓	
L Scapula	✓		
Manubrium	✓		
Sternal body	✓		
R Rib 1		✓	
L Rib 1	✓		
R Ribs	9		
L Ribs	11		

Element	Present	Absent	#
Atlas (C1)		✓	
Axis (C2)		✓	
C3-7	1		
T1-T12	6		
L1-L5	4		
R Os Coxa		✓	
L Os Coxa		✓	
Sacrum		✓	
Coccyx		✓	

RIGHT ARM	Present	Absent	#
Humerus	✓		
Radius		✓	
Ulna		✓	

LEFT ARM	Present	Absent	#
Humerus	✓		
Radius	✓		
Ulna	✓		

RIGHT HAND	Present	Absent	#
Carpals		✓	
Metacarpals		✓	
Phalanges		✓	

LEFT HAND	Present	Absent	#
Carpals		✓	
Metacarpals	3		
Phalanges		✓	

RIGHT LEG	Present	Absent	#
Femur	✓		
Patella	✓		
Tibia	✓		
Fibula	✓		

LEFT LEG	Present	Absent	#
Femur	✓		
Patella	✓		
Tibia	✓		
Fibula	✓		

RIGHT FOOT	Present	Absent	#
Calcaneus		✓	
Talus		✓	
Other tarsals		✓	
Metatarsals		✓	
Phalanges		✓	

LEFT FOOT	Present	Absent	#
Calcaneus	✓		
Talus	✓		
Other tarsals	4		
Metatarsals	5		
Phalanges	10		

COMMENTS:

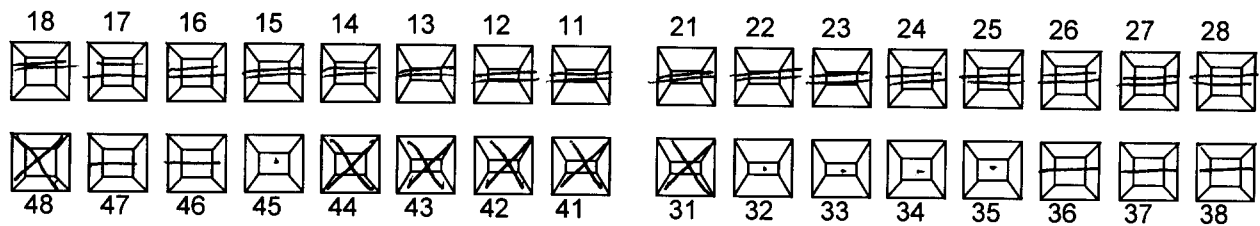
Case No
AV02 / 164B

Odontogram

Dental Findings in permanent teeth (notify temporary teeth specifically)

11	21
12	22
13	23
14	24
15	25
16	26
17	27
18	28

not recovered



48	38
47	37
46	36
45	35
44	34
43	33
42	32
41	31

Specific Description Of Crowns, Bridges and Dentures	
Further Findings Occlusion, attrition, Anomalies, smoker, Periodontal status etc.	The skull was not recovered
X-rays taken of	
Supplementary Examination	
Estimated age	Method

BODY RECOVERY REPORT. Site: (code) RAMCO Body/(Body Part)No. RV-02-164B
(Complete in ink. Do not write on reverse. Initial errors)

Recorder: (Full Name) DŽEVAD BELTAJONČ Time/Date: 19/07/2001

Body: Skeletonised - Partly Skeletonised - Saponified

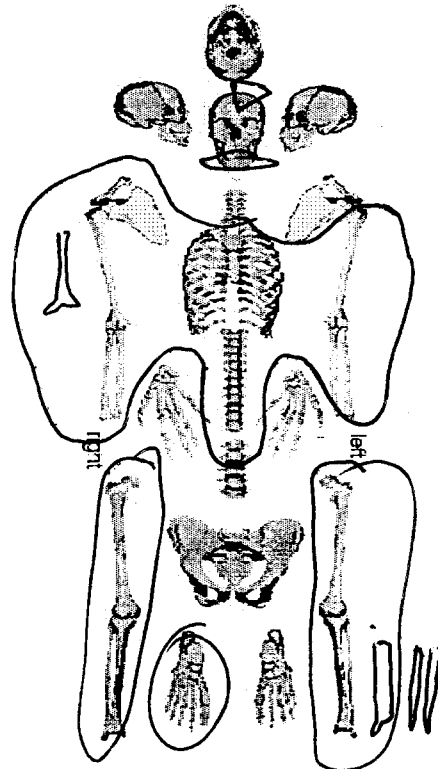

Coordinates Surveyed SECTOR "E"

Lies on:	Front	<u>Back</u>	Right Side	Left Side
Body:	<u>Extended</u>	Bent at hips	Tightly bent	
Left Arm:	Extended	<u>Bent at elbow</u>	Tightly bent	
Right Arm:	Extended	<u>Bent at elbow</u>	Tightly bent	
Left Leg:	Extended	<u>Bent at knee</u>	Tightly bent	
Right Leg:	Extended	<u>Bent at knee</u>	Tightly bent	

Clothing: (Using standard description list) SHORT SLEEVED BROWN SHIRT, GREY-DIVING TROUSERS WITH WAIST BELT-BLACK LEATHER, ANKLE HEIGHT TRAINER-(BLUE COLOR) CONTAINING GREY SOCKS WITH FOOT BONES INSIDE
 Artefacts associated to body: (i.e. Documents/Jewellery/Watch) WRIST WATCH; TABACCO BOX Blindfold: Y/N Ligature: Y/N

Additional Information: (Factual observations and information to assist in determining cause of death or identification of victim)

YELLOW METAL WRIST WATCH WITH WHITE PLATE, WITH STRAP
- FACTORY PRODUCED METAL TABACCO BOX - DAMAGED BY CORROSION
- EXTRA BONES; RIGHT HUMERUS; LOWER PIECE OF TIBIA AND 2 FIBULAS)



This statement, consisting of one page, is true to the best of my knowledge and belief and I make it knowing, that if it is tendered in evidence I shall be liable to prosecution if I have wilfully stated in it anything I know to be false or do not believe to be true.
 Signed _____ Date _____ MJH 2001

X0123899

IZVJESTAJ O PRONADJENOM TIJELU. Lokacija: (naziv) _____ Tijelo/(Dio tijela)br. RV-02-164 B
(Popuniti hemijskom olovkom, ne pisati na poledjini. Staviti inicijale pored ispravljene greške)

Bilježnik: (puno ime) _____ Time/Date: 19/07/2001

Tijelo: Skeletinizirano - Djelimično skeletinizirano - Saponificirano

Koordinate SEKTOR, E"

Lezi na:	prednjoj strani	<u>na leđjima</u>	Desna strana	Lijeva strana
Tijelo:	<u>ispruzeno</u>	savijeno u bokovima	jako savijeno	
Desna ruka:	ispruzena	<u>savijena u laktu</u>	jako savijena	
Desna ruka:	ispruzena	<u>savijena u laktu</u>	jako savijena	
Lijeva noga:	ispruzena	<u>savijena u koljenu</u>	jako savijena	
Desna noga:	ispruzena	<u>savijena u koljenu</u>	jako savijena	

Odjeca: (koristiti standardnu listu kod opisa) KOŽUŠKA KRATKI RUKAVI U BRADN BOJE;
ANTALONE SUB U POJASU KRIŠ CRNI-KOŽA; DUBOKA PATIKA PLAVE BOJE UNUTRA
ČARAPA BIVA SA STOPALOM

Predmeti nadjeni uz tijelo: (npr. Dokumenti/nakit/sat) povez za oci: Da (Ne) povez za ruke: Da (Ne)

RUČNI SAT; TABAKERA

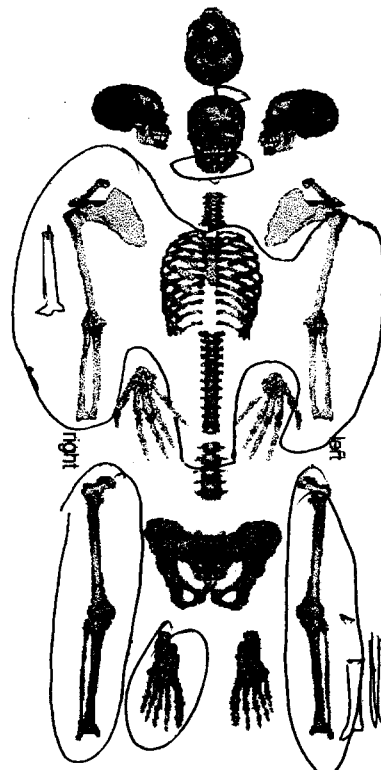
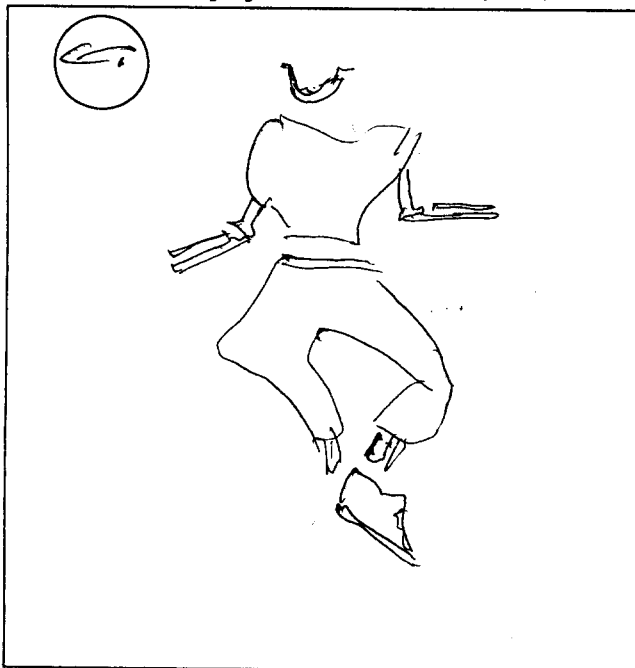
Dodatne informacije: (Cinjenicne observacije i informacije od pomoci za odredjivanje uzroka smrti ili identifikacije zrtve)

RUČNI SAT ŽUTI METAL BJELE PLOČA SA KATJOM

TABAKERA METALNA FABIČIČKA PROIZVODNJA - OŠTEĆENA KORUZIJOM

- EKSTRA KOSTI : HUMERUS DESNI; DONJI OKRAJAC TIBIJE I 2 LIŠNEJ

Polozaj tijela (naznaciti pravac sjevera)



Ova izjava koja se sastoji od 1 strane, je istinita, u skladu sa mojim najboljim znanjem i vjerovanjem, i ja znam da cu, ako se ista prilozi kao dokazni materijal, odgovarati za krivicno djelo ukoliko svojom voljom izjavim/navedem nesto sto je lazno ili nesto za sta ne vjerujem da je istina.

Potpis

Datum

preveo: Zvezdan Karadzin (MJH 2001)

Surrogate Sheet

PHOTOGRAPHS

Black & White

ERN: X012-3900- X012-3901

SYNOPSIS / DESCRIPTION OF EVIDENCE

FLUROSCOPY IMAGES ATTACHED TO THE AUTOPSY REPORT OF THE
BODY RV02/164BP

Cross Reference ?

If Yes ERN