

1. Photo ✓ **CEES/WAN**
2. Log Checked ✓ **CEES**
3. X-ray ✓ *C. Godling*
4. Path 01
02
5. Anth
6. 2nd Photo

X0016497



United Nations International Criminal Tribunal for
former Yugoslavia

AUTOPSY REPORT
CR03 GRAVE SITE

CASE NO: CR03B639

AUTOPSY DATE: 10.09.98

Sex determined by soft tissue: NOT ASCERTAINABLE

Height by direct measurement: NOT ASCERTAINABLE

Body build: NOT ASCERTAINABLE

SUMMARY:

In my opinion the cause of death of CR03B639 is not ascertainable.

Comment:

The left lower leg of an adult person with old fractures of the left tibia and left fibula without any obvious peri-mortem injury.

This formal report is based upon the autopsy report that I prepared at the time of my examination, and both reports truly and accurately reflect my findings.

Signed:


Dr. W. Marty Spec. Forensic Med., University of Zürich

Date: 10.09.98

CLOTHING: YES

1 pair of trousers
1 pair of underpants
1 handkerchief (ligature?)

BLINDFOLD/BANDAGE: NONE**LIGATURE: PROBABLY****PERSONAL EFFECTS: YES**

CR03B639.1 -- 1 small bag with flint stones (recovered from left pocket)
CR03B639.2 -- 1 handkerchief in the right pocket, probably used as a ligature

IDENTIFICATION PAPERS OR ID CARD: NONE**PRESERVATION:**

Decomposed

BODY PARTS MISSING:

Pelvis, right femur, teeth, thorax, upper limbs, head.

COMMINGLING: NO**HEAD HAIR: NO**

Colour:

Length:

BEARD/MOUSTACHE/BODY HAIR: N/A**SKIN CHARACTERISTICS:**

Surgical scars: N/A

Injury scars: N/A

Old injuries:

Old fracture of the left tibia near the ankle and old fracture of the tibia in the middle part.

Other identifying characteristics: None

DENTAL STATE: N/A**TRAUMA RELATED TO DEATH: NONE SEEN****RECENT TRAUMA UNRELATED TO DEATH: NONE SEEN****EXTERNAL EXAMINATION: N/A****INTERNAL ORGANS Recognisable: NO**

RECOVERED OBJECTS: X0016499

Projectiles:

Many very small metallic fragments in the region of the left femur as a possible site of bullet contact. Not recovered.

Other objects: None

HANDED TO: SOCO

BONE FLUOROSCOPED BY: Chris Gosling

X0016500

CASE NO:
CR 03
B 639



United Nations International Criminal Tribunal for former Yugoslavia

.....CR 03..... GRAVE-SITE, BOSNIA

AUTOPSY REPORT

AUTOPSY DATE: 9.19.98 AUTOPSY ROOM: Vjeko

PATHOLOGIST: Dr. W. Reutzy

EXTERNAL EXAMINATION

SEX FROM SOFT TISSUE EVIDENCE Male() Female() Not possible

If sex determination possible, what structures are present?

BODY BUILD (if ascertainable) N/A

HEIGHT (ONLY GIVE IF POSSIBLE BY DIRECT MEASUREMENT): CM N/A

For summary see page 8

LIGATURE probably BLINDFOLD none

CLOTHING yes BANDAGE none

List as removed (Detail on special form)

1 trouser

1 Underpant

1 handkerchief (ligature?) -> loco

Initials.....ky

AUTOPSY REPORT (CONTINUED)

CASE No.
CR03
B639

PERSONAL EFFECTS (handed to:)

how

Brief details (e.g., "wallet", no need to list contents which will be listed by evidence gatherers)

Item	Recovered from	Item	Recovered from
1 small bag with flint stones,	left pocket	CR 03 B639.1	
1 handed handkerchief	in the right pocket,	probably used as handkerchief ^{kerchief}	CR 03 B639.2
IDENTIFICATION PAPERS OR ID CARDS		how	

PRESERVATION: all computerized

Initials..... *My*.....

AUTOPSY REPORT (CONTINUED)

CASE No.
CP 03
B 639

BODY PARTS MISSING: pelvis, right femur, feet,
thorax, upper limbs, head

COMMINGLING; Yes () No (X)

If so, give details

HAIR: Present: Yes () No () N/A

Colour:

Length (longest part): cm

Other features (eg,wavy,curly,straight):

BEARD: Yes () No () Unknown (X)

MOUSTACHE: Yes () No () Unknown (C)

Colour: Length:

Colour: Length:

TATTOOS: n/a

Initials..... My.....

AUTOPSY REPORT (CONTINUED)

CASE No.
CR03
R639

SCARS: Would any scars still be visible Yes () No () *N/A*

If present give details (ie surgical, injury):

OLD INJURIES: (SPECIFY SITE AND DETAILS) See also Anthropologist's Report *photo taken*

Old fracture of the left tibia near the ankle and old fracture of the tibia in the middle part

ANY OTHER IDENTIFYING CHARACTERISTICS: *None*

DENTAL STATE:

Jaws retained for odontologist Yes() No() (see notes) *N/A*

If not retained give brief description (eg: edentulous, severe caries, lost post-mortem etc.)

(see attached dental chart)

Restoration work: see separate form

Initials.....*ky*.....

AUTOPSY REPORT (CONTINUED)

CASE No.
CR03
B639

TRAUMA RELATED TO DEATH (List and record on body diagrams) N/A

Were any bones/skull reconstructed by anthropologist: Yes() No()

If yes, which:

DESCRIPTION OF INJURIES (Please number) none

Initials.....*ky*.....

AUTOPSY REPORT (CONTINUED)

CASE No.
CR 03
B639

INTERNAL ORGANS Recognisable: Yes () No

RECOVERED OBJECTS:

PROJECTILES ~~None~~ yes

Was the body fluoroscoped Yes () No () Name of Radiographer:

Number of bullets seen on fluoroscopy: Number found:

Position of bullets in body (please note if complete, jacket only, core only, or fragments, small/medium/large calibre. Give types if more than one type present)

1. A lot of very small metallic pieces in
2. the region of the left femur. as a
3. possible sign of bullet contact,
4. not retained

- 5.
- 6.
- 7.
- 8.
- 9.
- 10.
- 11.
- 12.
- 13.
- 14.

OTHER OBJECTS:

Handed to:

Initials..... *My*

AUTOPSY REPORT (CONTINUED)

CASE No.
CR 03
B 639

SUMMARY

The left lower leg
~~Parts of the skeleton~~ of an adult
person with old fractures on the
left tibia and left fibula without
any ^{obvious} traces of ^{injury} perinatal trauma.

It is my determination that the ^{cause of} death of CR 03 B 639 was caused by:
ix not ascertained.

.....and I so certify.

Signed.....

[Signature]

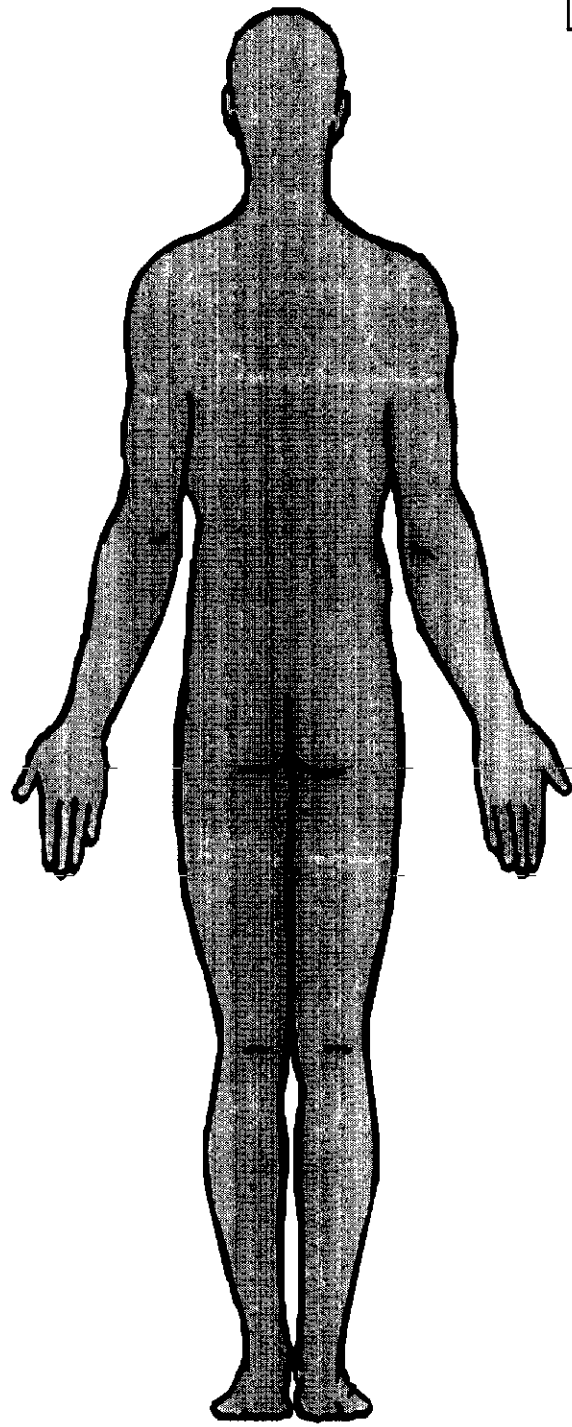
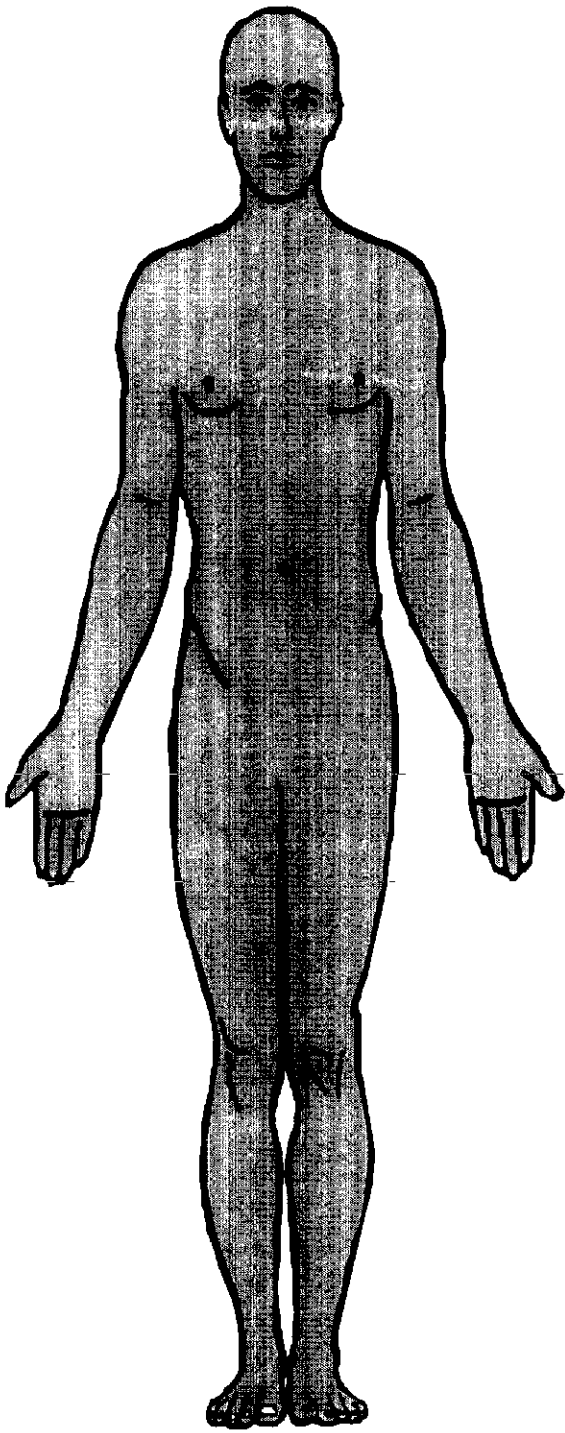
Qualifications.....

Spec. Forensic Med. Univ Zurich

Date.....

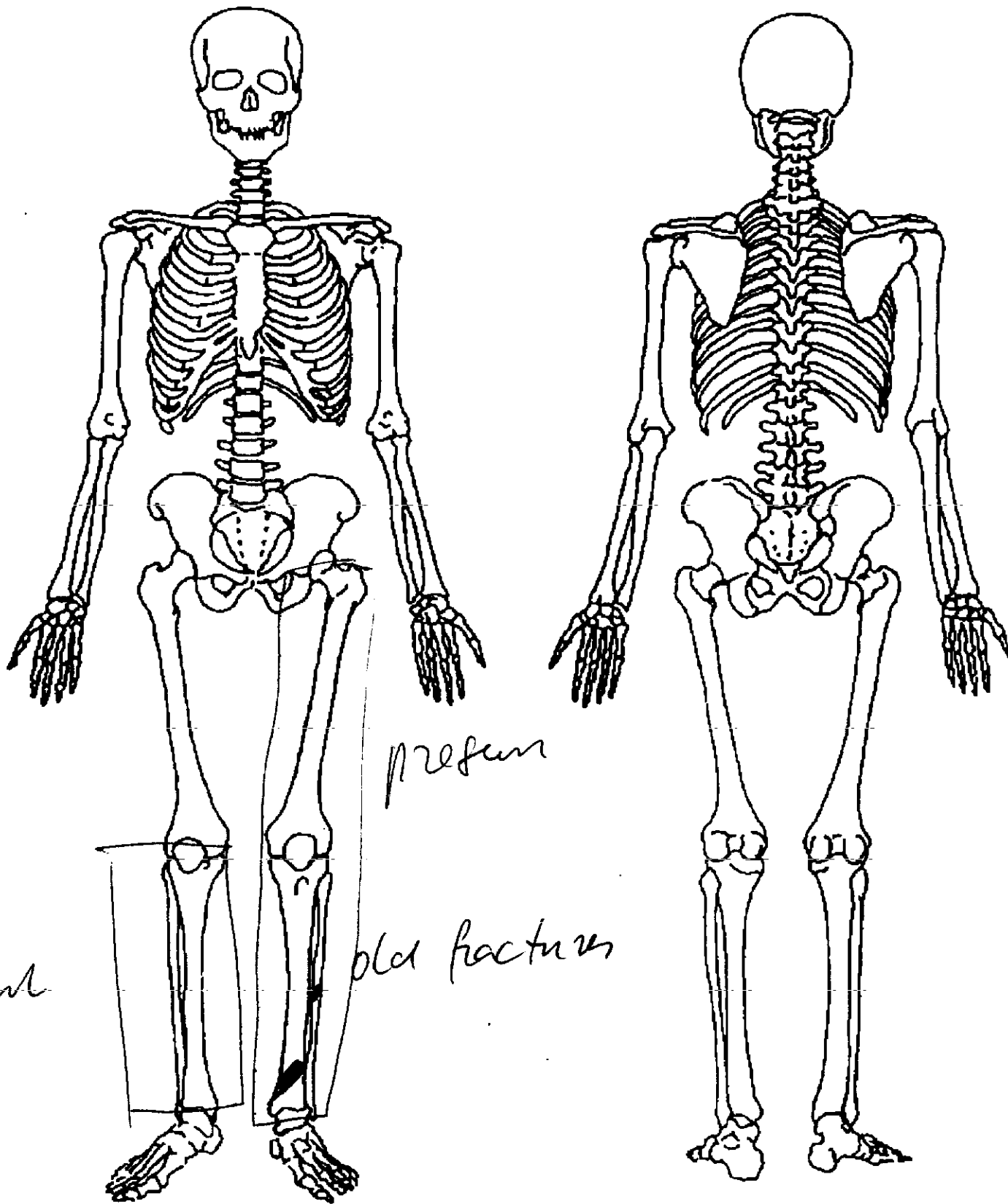
autopsie finished
10.9.78

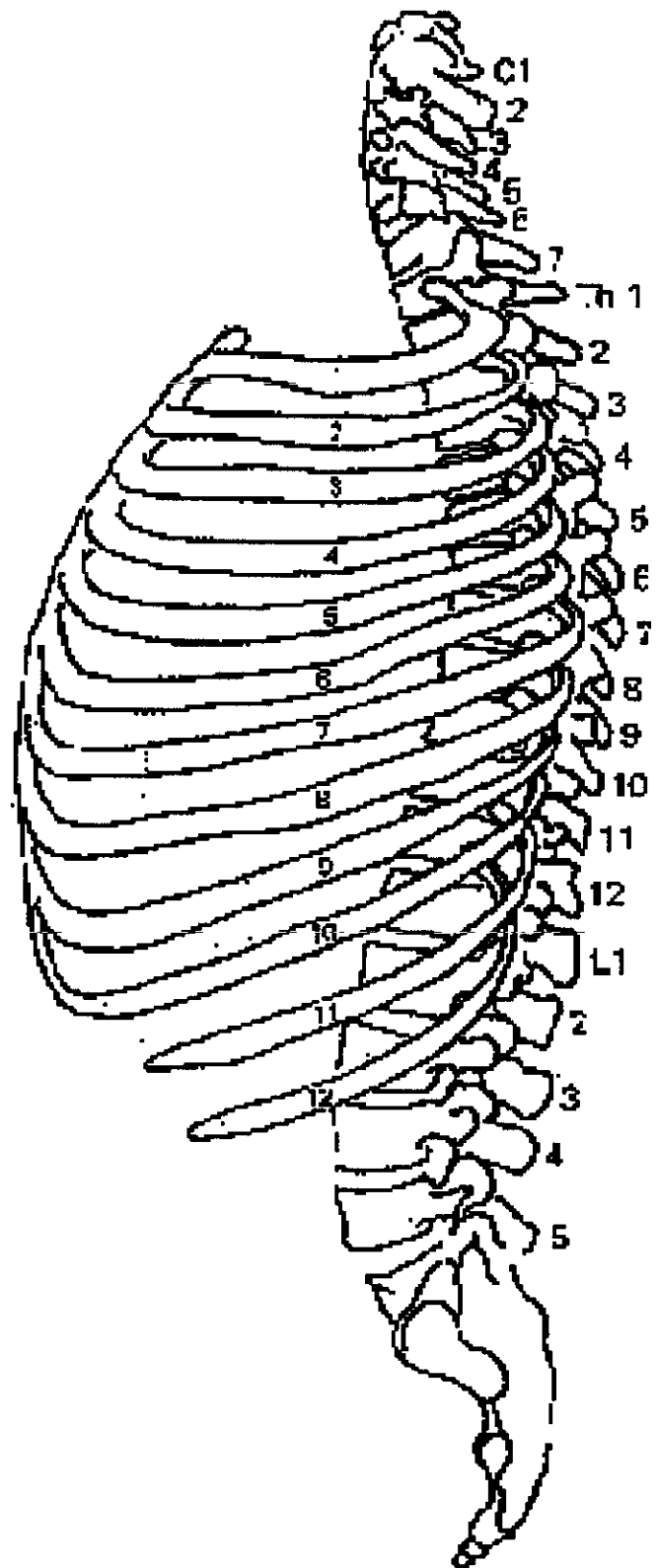
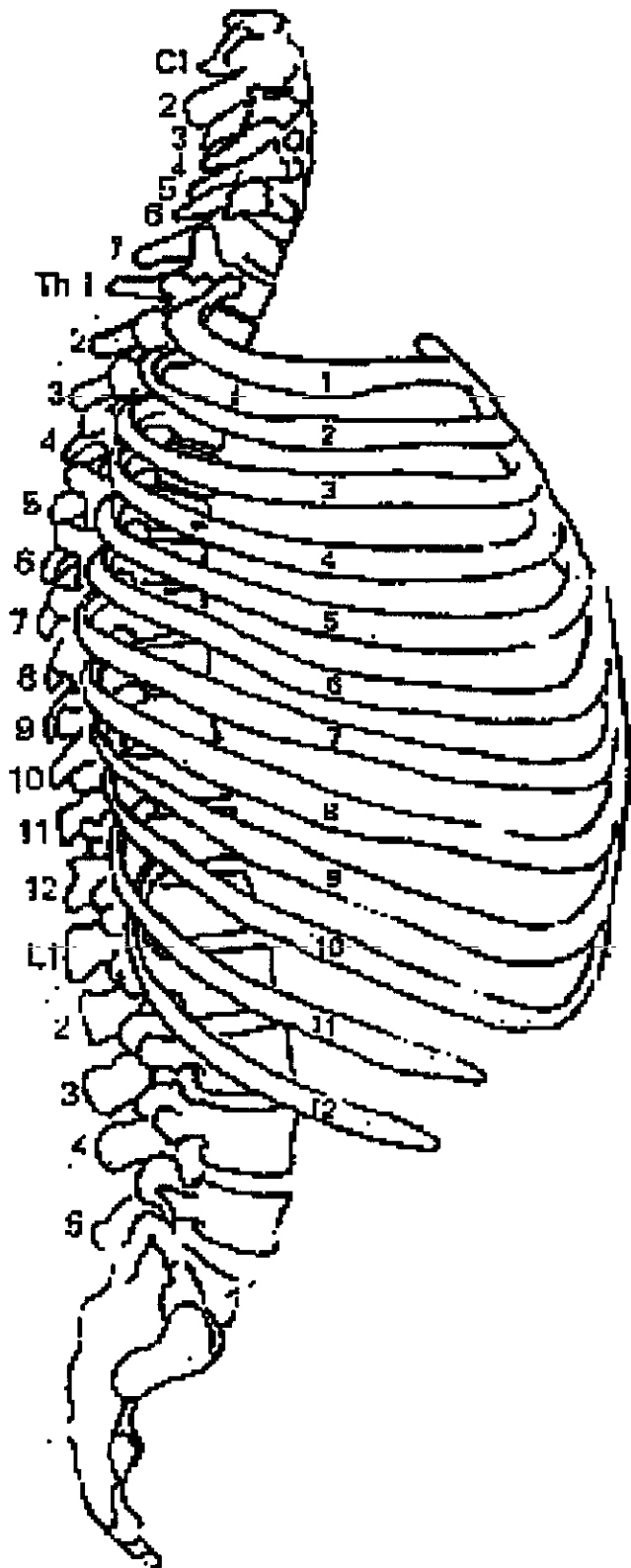
--



Initials.....

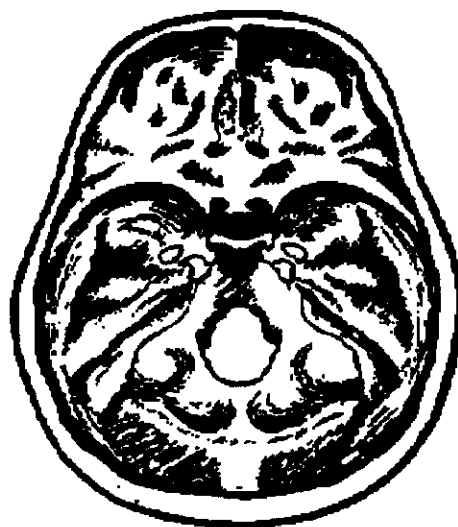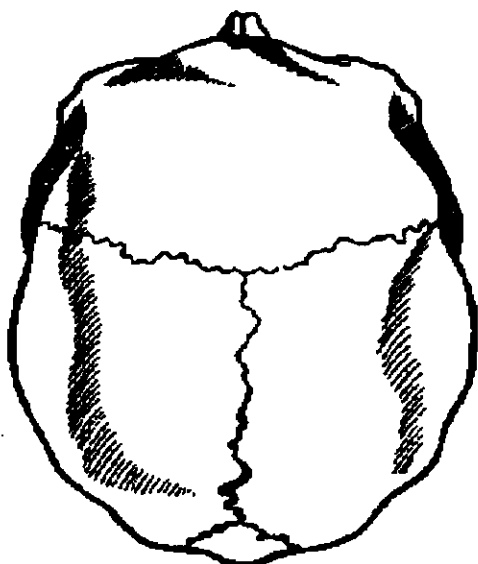
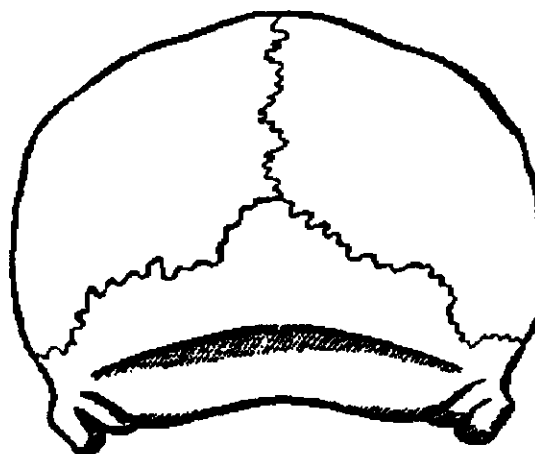

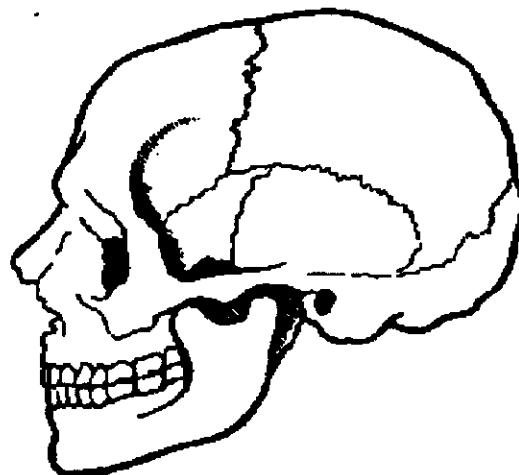
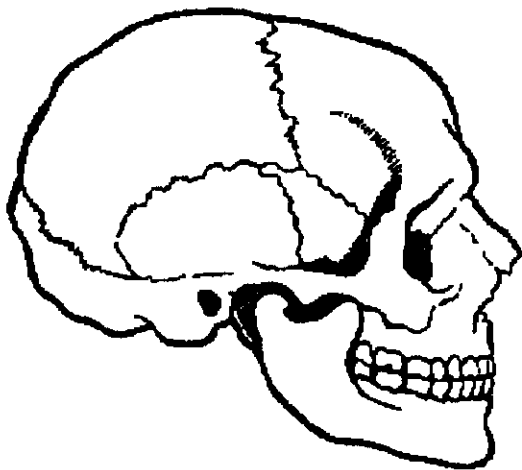
CASE No.





Initials.....

CASE No.



Initials.....

PHOTO - 180/35

CLOTHING (AFTER WASHING)

CASE No:

**CR03
8639**

Examiner **FRANS / FRAN**

- Please describe colour, label, design, logo(s), and any additional features including types of pockets, repairs etc.
- Record possible bullet holes on diagrams

10.9.98

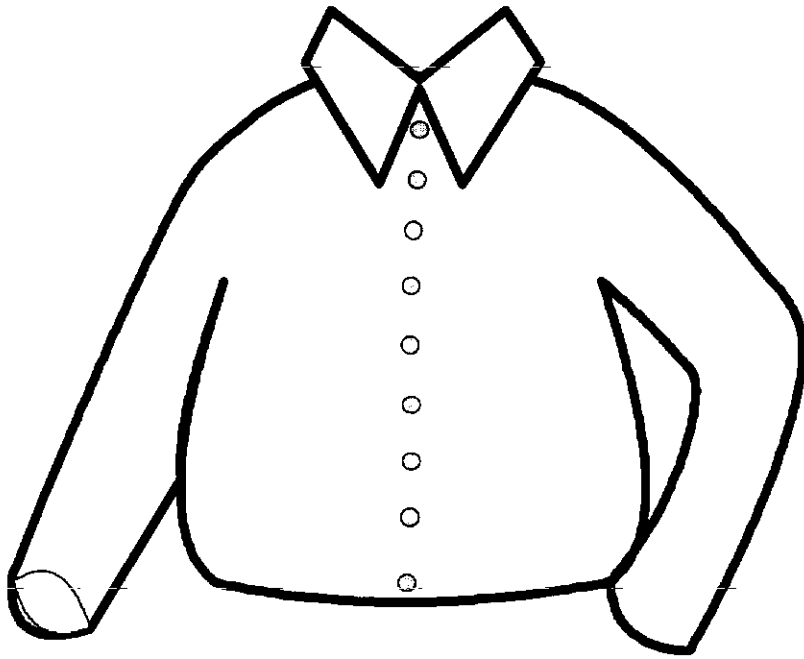
Trousers	One pair of black trousers. Pockets on both sides. Zip fly. Patches on both thigh/knee areas. Black belt through loops in trousers. See diagram
Jacket	
Sweater	
Shirt	
Vest (undershirt)	
Under-pants Sports shorts	One pair of nylon sports shorts - colour unrecognisable - tie dyed with blue stitching. Tear on bottom right side
Belt	Black belt with buckle
Socks	
Footwear	
Other	

X0016513

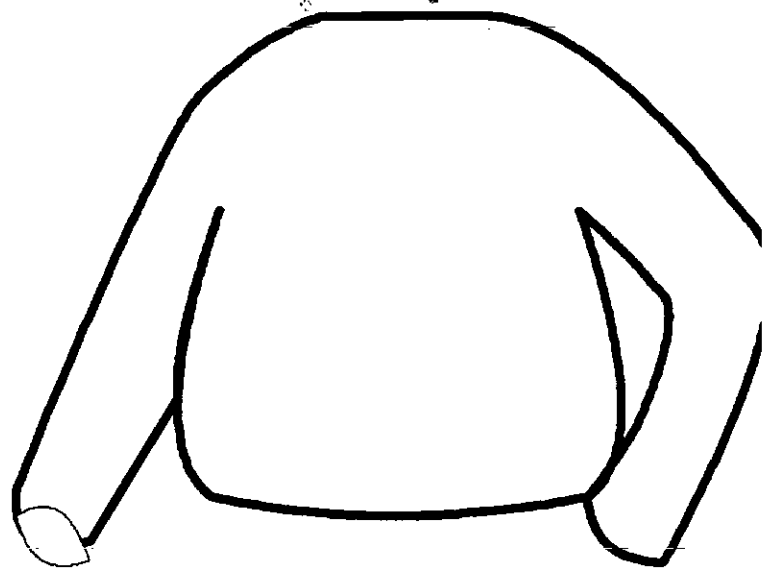
JACKET

X0016514

CASE No:
CR03
B63A

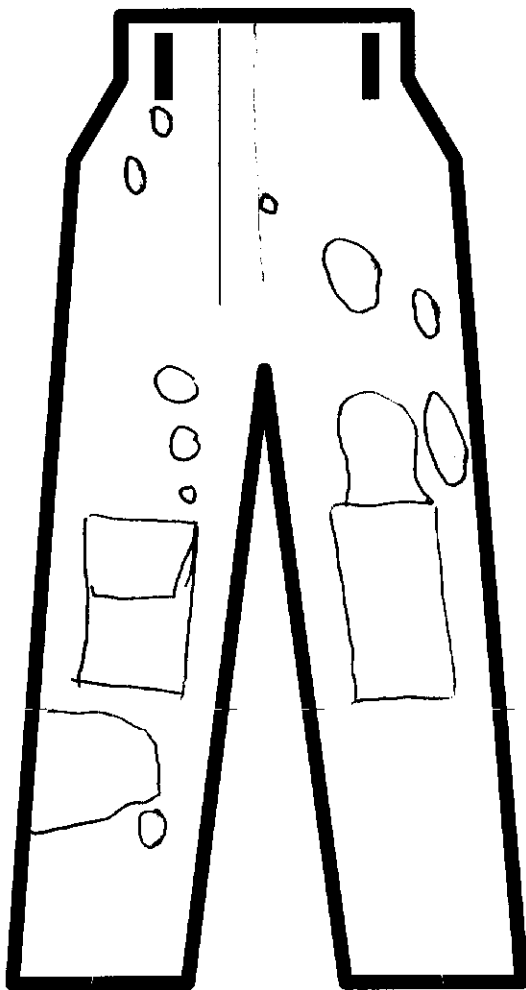


Front




Back

TROUSERS



Front

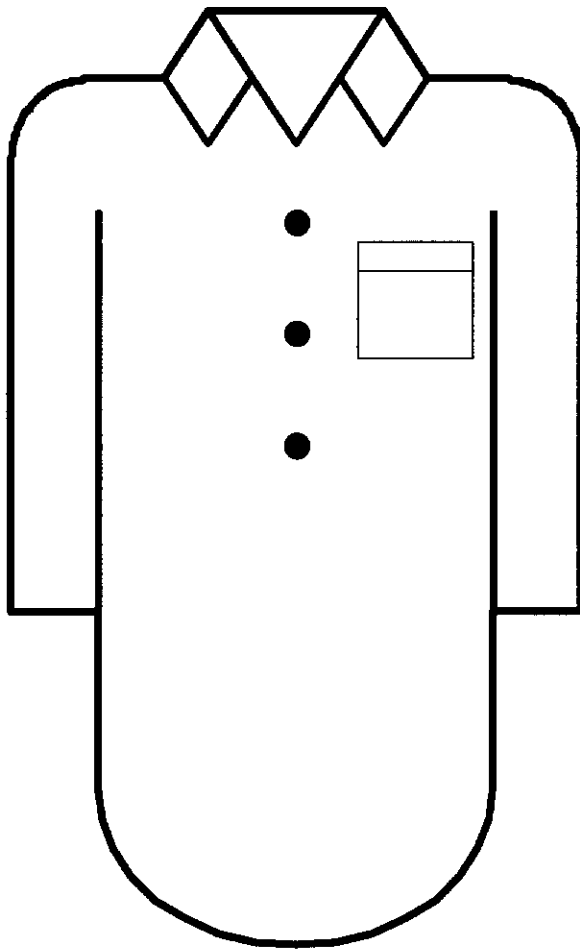


Back

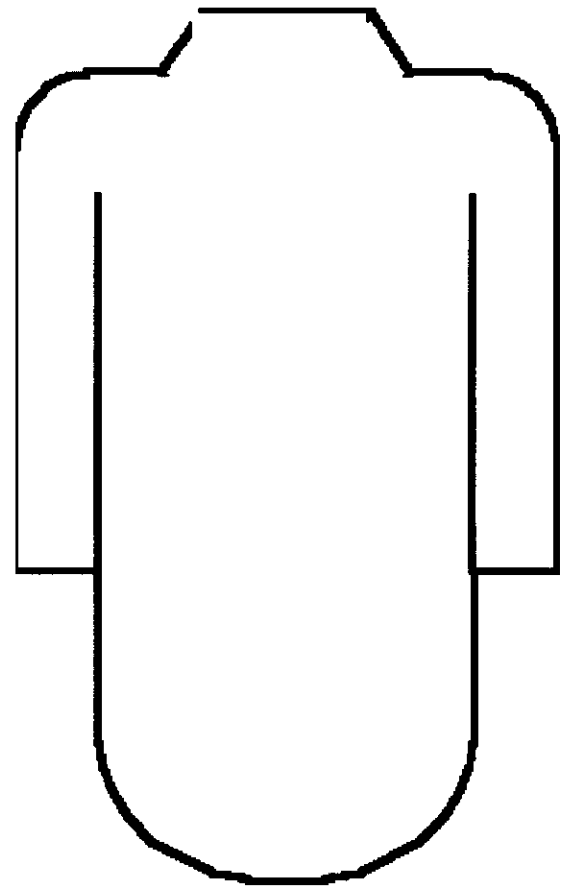
SHIRT

X0016515

PM NO.:




Front




Back

VEST



Front



Back

X0016516



United Nations International Criminal Tribunal for the former Yugoslavia

.....CRO3.....GRAVE-SITE, BOSNIA

ANTHROPOLOGY FORM

Body #.....B639.....

Date.....9.1.98.....

Anthropologist.....J. Powers + S. Martin.....

Pathologist.....W. Marty.....

SEX: MALE / FEMALE / INDETERMINATE (circle one)

Os coxae:

Subpubic concavity:.....(1/0/NO)
Ischiopubic ramus ridge.....(1/0/NO)
Greater Sciatic notch.....(1/2/3/4/5/NO)
Ventral arc:.....(1/0/NO)
Preauricular sulcus.....(1/2/3/4/NO)

Cranium:

Nuchal crest:.....(1/2/3/4/5/NO)
Mastoid process.....(1/2/3/4/5/NO)
Supraorbital margin.....(1/2/3/4/5/NO)
Prominence of Glabella.....(1/2/3/4/5/NO)
Mental eminence.....(1/2/3/4/5/NO)

AGE RANGE ADULTS..... > 17

Table with 4 columns: Phase, Range, Mean. Rows: Suchey-Brooks, Iscan-Loth.

AGE RANGE SUBADULTS.....

Dental Calcification

Table with 2 columns: Tooth, Phase. Row: (crossed out)

Union of Epiphyses

Table with 3 columns: Epiphyses, Fusion. Rows: Femur-L, Tibia-L, Fibula-L, Tibia-R, Fibula-R. Fusion: closed, closed, closed, closed, closed. Includes a bracket and '> 17'.

STATURE (cm)..... 173.75 +/- 6.54

Max.Length Femur (R/L)..... 47.2

Max.Length Tibia (R/L).....

Max.Length Fibula (R/L).....

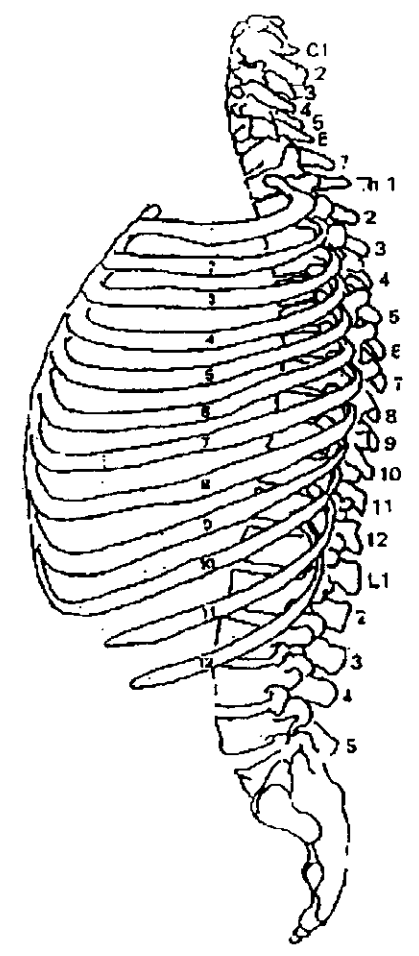
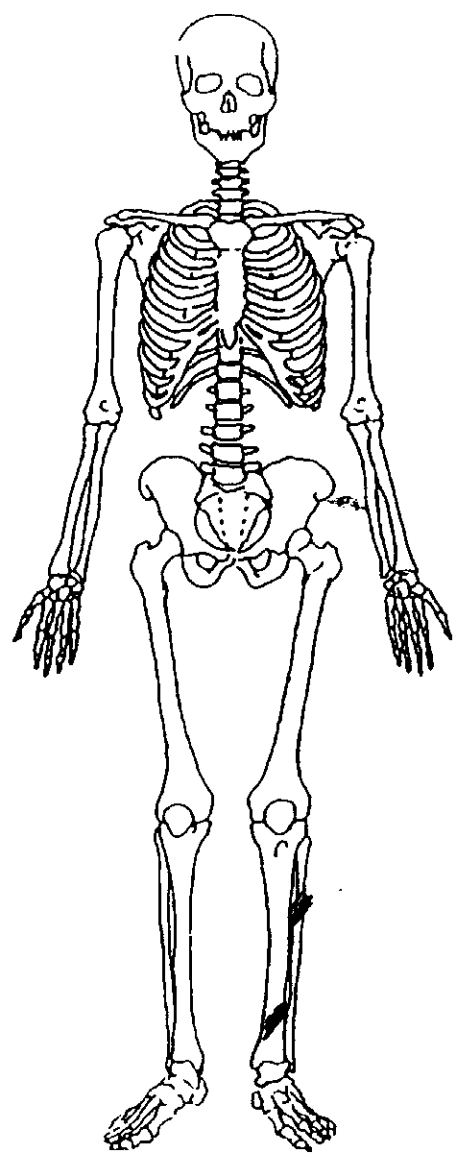
Other long bone (R/L).....

Formula Used Femur

CASE No.
CR03
B639

RADIOGRAPHY FINDINGS

BULLET LOCATIONS



OTHER REMARKS

Old fractures of the distal
tibia left over fibula left.
no bullets.

X0016517

IMAGING

Thermal Paper:

~~2~~ 2

24 - 30 Film:

RADIOGRAPHER:

C. Goring


PATHOLOGIST:

PM TECH:

Uter

Old pattern of the
left A tube

X0016518



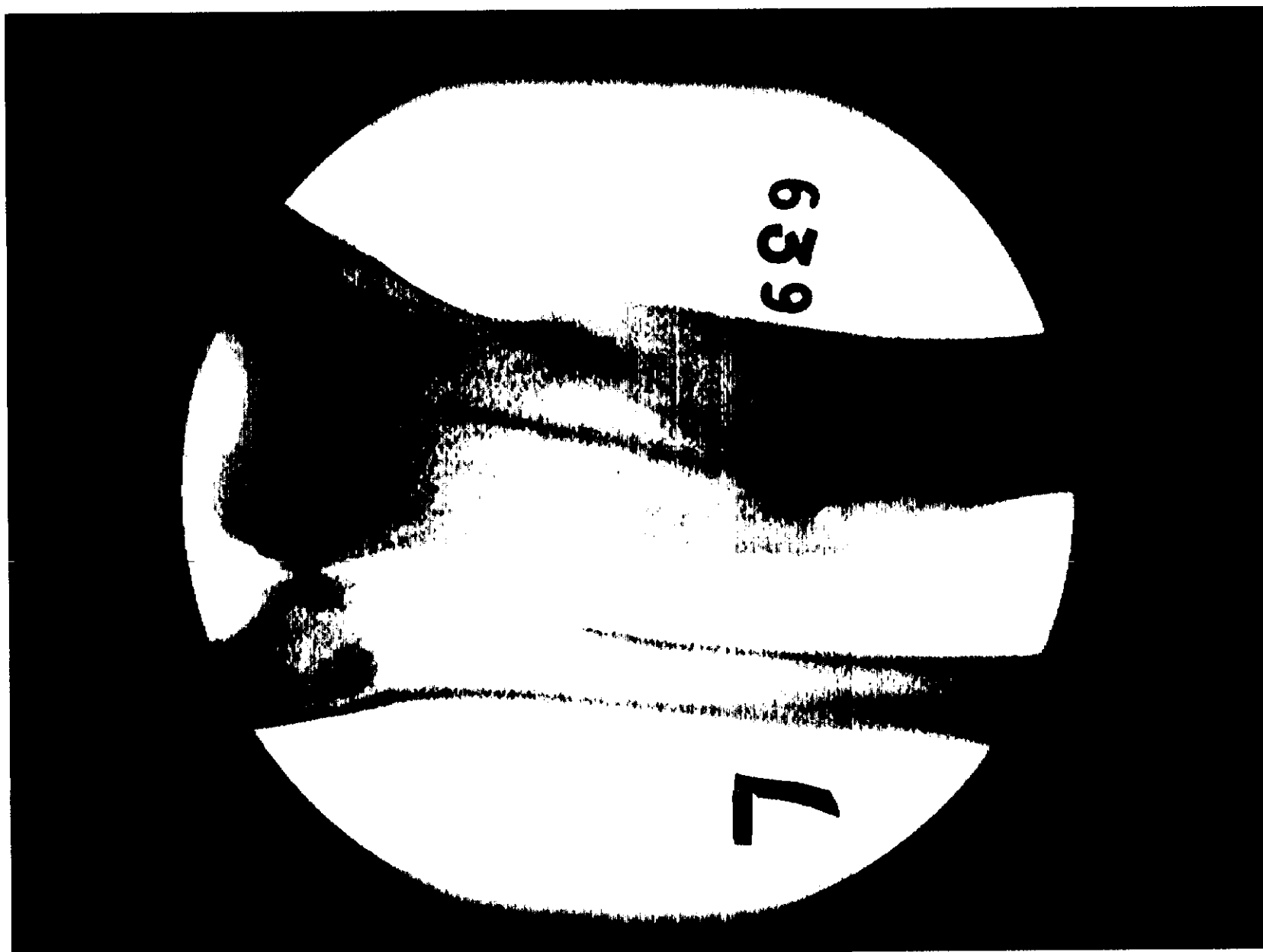
CR03

B639

9/9/98

Old fracture
of the tibia (left)

X0016519



CR03

B639

9/9/98