



AUTOPSY REPORT
NOVA KASABA GRAVE SITE

CASE NO: NK04 032B

AUTOPSY DATE: 20.09.99
MORTUARY: Visoko

SUMMARY:

These were remains of an almost skeletonized body, complete in all its parts.

From the anthropological data, the person was male, aged between 31 and 65 years, and measured 168 +/- 7.7 cm in height.

The autopsy revealed no injuries or other ante mortem traumatic evidence.

CAUSE OF DEATH:

It is my determination that the cause of death in case number **NK04 032B** was:
Unascertained

This formal report is based upon the autopsy report that I prepared at the time of my examination. Both reports truly and accurately reflect my findings.

Signed.....

Dr Enrico Manfredi, Medico Chirurgo, Specialista in Medicina Legale

Date: 20.09.99

A. GENERAL DESCRIPTION OF REMAINS:

These were remains of an almost skeletonized body, complete in all its parts

B. CLOTHING:

- Black and red overalls
- One sports shoe

X 0045548

OTHER ITEMS:

- Yellow metal ring

C. IDENTIFYING FEATURES:

Sex:

From examination of soft tissues: Not possible

From anthropology details: Male

Age range (from anthropology data): 31 - 65

Build: Not possible

Height (cm):

From estimation of intact body: Not possible

From anthropology data: 168.3 +/- 7.7

Hair:

Head hair: Blond hair, 3 cm in length, at left side of the skull

Facial hair: Not possible

Teeth:

General description: Almost complete dentition

Retained for dentist: No

Tattoos: Not possible

Scars: Not possible

Other features: None

D. BODY PARTS MISSING: See Anthropology Report

E. INJURIES:

None

F. INTERNAL TISSUES:

Brain

H. SAMPLES AND ITEMS RETAINED:

SOCO: Ronnie Govender

Bullets/Shrapnel:

None

Anthropology:

Pubic symphysis
Left 4th rib

DNA:

Right femur diaphysis
Tooth

X 0045549

Other:

None



United Nations
International Criminal Tribunal
for former Yugoslavia

CASE NO:

**NK 04
032B**

GRAVE SITE: NOVA KASABA

MORTUARY: VISOKO

DATE: 20.9.99

PATHOLOGIST: E. MANFREDI

ANTHROPOLOGIST: S. MARTIN

AUTOPSY REPORT

A. GENERAL DESCRIPTION OF REMAINS

These were remains of an almost skeletonized body, complete in all its parts.

A handwritten signature in black ink, consisting of a large, stylized loop followed by a vertical stroke.

X 0045551

B. CLOTHING (after washing)

DISPOSAL
KEPT BODY BAG

Black and red overall
One sport shoe

X
X

OTHER ITEMS

Yellow metal ring

DISPOSAL
KEPT BODY BAG
X

A handwritten signature or mark consisting of a large, stylized 'O' or 'Q' shape followed by a long, sweeping line that curves downwards and to the right.

C. IDENTIFYING FEATURES

X 0045552

SEX (FROM EXTERNAL EXAMINATION)

NOT POSSIBLE

BUILD

NOT POSSIBLE

HEIGHT (ONLY IF INTACT BODY)

HAIR (COLOUR, LENGH, DISTRUBUTION)

HEAD: blond (3 cm long) hair at the lefet side of the skull

FACIAL

NOT POSSIBLE

BODY (if appropriate)

NOT POSSIBLE

TEETH (general description)
Almost complete dentition

TATTOOS (general description and site)

NOT POSSIBLE

SCARS

NOT POSSIBLE

OTHER FEATURES



NK 04
032B

D. ANTHROPOLOGY DETAILS

(i) SEX: MALE/FEMALE/INDETERMINATE (circle one)

X 0045553

Os coxae: R/L

Cranium:

- Subpubic concavity (1) NO
- Ischiopubic ramus ridge (1) NO
- Greater Sciatic notch (1/2/3) 4 / 5 / NO
- Ventral arc (1) NO
- Preauricular sulcus (1/2/3) 4 / NO

- Nuchal crest (1/2/3/4) 5 / NO
- Mastoid process (1/2/3/4) 5 / NO
- Supraorbital margin (1/2) 3 / 4 / 5 / NO
- Prominence of Glabella (1/2/3) 4 / 5 / NO
- Mental eminence (1/2) 3 / 4 / 5 / NO

(ii) AGE RANGE ADULTS 31-65

	Phase	Range	Mean
Suchey Brookes R/L	<u>4/4</u>	<u>15-71</u>	<u>43.7</u>
Ischan-Loth R/L	<u>5</u>	<u>20.6-63.0</u>	<u>—</u>

(iii) AGE RANGE SUBADULTS

Dental Calcification		Union of Epiphyses	
Tooth	Phase	Epiphyses	Fusion
.....
.....
.....
.....
.....
.....

closed

(iv) STATURE (cm) 168.3 +/- 7.7

- Max Length Femur (R/L) 443 mm
- Max Length Tibia (R/L)
- Max Length Fibula (R/L)
- Other long bone (R/L)
- Formula Used

AK04
032B

X 0045554

(v) SKELETAL INVENTORY

Element	Present	Absent	#
CRANIUM	✓		
Frontal	✓		
R Parietal	✓		
L Parietal	✓		
Occipital	✓		
R Temporal	✓		
L Temporal	✓		
R Maxilla	✓		
L Maxilla	✓		
MANDIBLE	✓		

Element	Present	Absent	#
R.Clavicle	✓		
L Clavicle	✓		
R Scapula	✓		
L Scapula	✓		
Manubrium		✓	
Sternal body		✓	
R Rib 1	✓		
L Rib 1		✓	
R Ribs	✓		10
L Ribs	✓		11

Element	Present	Absent	#
Atlas (C1)	✓		
Axis (C2)	✓		
C3-7	✓	(c5-6)	3
T1-T12	✓		7
L1-L5	✓		5
R Os Coxa	✓		
L Os Coxa	✓		
Sacrum	✓		
Coccyx	✓		

RIGHT ARM	Present	Absent	#
Humerus	✓		
Radius	✓		
Ulna	✓		

LEFT ARM	Present	Absent	#
Humerus	✓		
Radius	✓		
Ulna	✓		

RIGHT HAND	Present	Absent	#
Carpals	✓		8
Metacarpals	✓		5
Phalanges	✓		10

LEFT HAND	Present	Absent	#
Carpals	✓		7
Metacarpals	✓		5
Phalanges	✓		14

RIGHT LEG	Present	Absent	#
Femur	✓		
Patella	✓		
Tibia	✓		
Fibula	✓		

LEFT LEG	Present	Absent	#
Femur	✓		
Patella	✓		
Tibia	✓		
Fibula	✓		

RIGHT FOOT	Present	Absent	#
Calcaneus	✓		
Talus	✓		
Other tarsals	✓		5
Metatarsals	✓		5
Phalanges	✓		7

LEFT FOOT	Present	Absent	#
Calcaneus	✓		
Talus	✓		
Other tarsals	✓		4
Metatarsals	✓		5
Phalanges	✓		9

COMMENTS:

SESAMOID ✓

X 0045555

E. INJURIES

(i) fluoroscopy findings

Radiographer Bruno Tonelli

PRINT TAKEN

YES NUMBER

(ii) MAIN INJURIES DESCRIBED (Please number and also use diagrams)

HEAD AND NECK

PROBABLY ANTE MORTEM
PROBABLY POST MORTEM
CAN'T TELL

LIMBS

TRUNK

F. INTERNAL TISSUES (if not covered under injuries)

Brain



G. PHOTOGRAPHS TAKEN

photographer Ronny Govender

- 1 overview of the body
- 2
- 3
- 4
- 5
- 6
- 7
- 8
- 9
- 10

X 0045556

H. SAMPLES AND ITEMS RETAINED
(other than clothing and possessions)

SOCO Ronny Govender

BULLETS/SHRAPNEL (description and site)

refers fluoroscopy
Print number

exhibit
No.

ANTHROPOLOGY

Pubis sinphisys
Left 4th rib

DNA

Right femur diaphysis
Thoot

OTHER



X 0045557

I. SUMMARY OF FINDINGS AND CONCLUSIONS

These were remains of an almost skeletonized body, complete in all its parts.

From the anthropological data the person was male, aged 31-65 years old and measured 168+/- 7, 7 cm in high.


The autopsy revealed no injuries or other ante mortem traumatic evidences.

CAUSE OF DEATH

It is my determination that the cause of death in case no: **NK 04/032B**
UNASCERTAINED

was

SIGNED

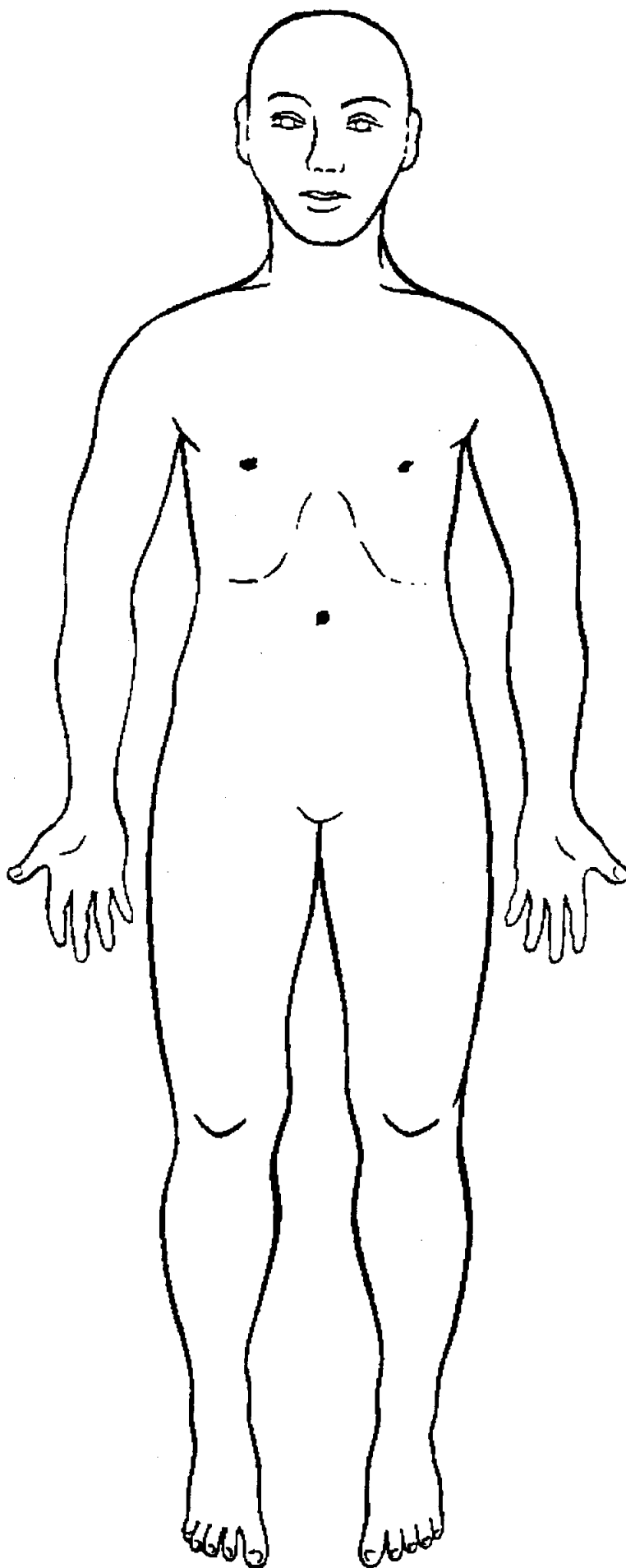


DR. ENRICO MANFREDI
MEDICO CHIRURGO, SPECIALISTA IN MEDICINA LEGALE
DATE: 20.9.99

CASE NO:

NK 02
032B

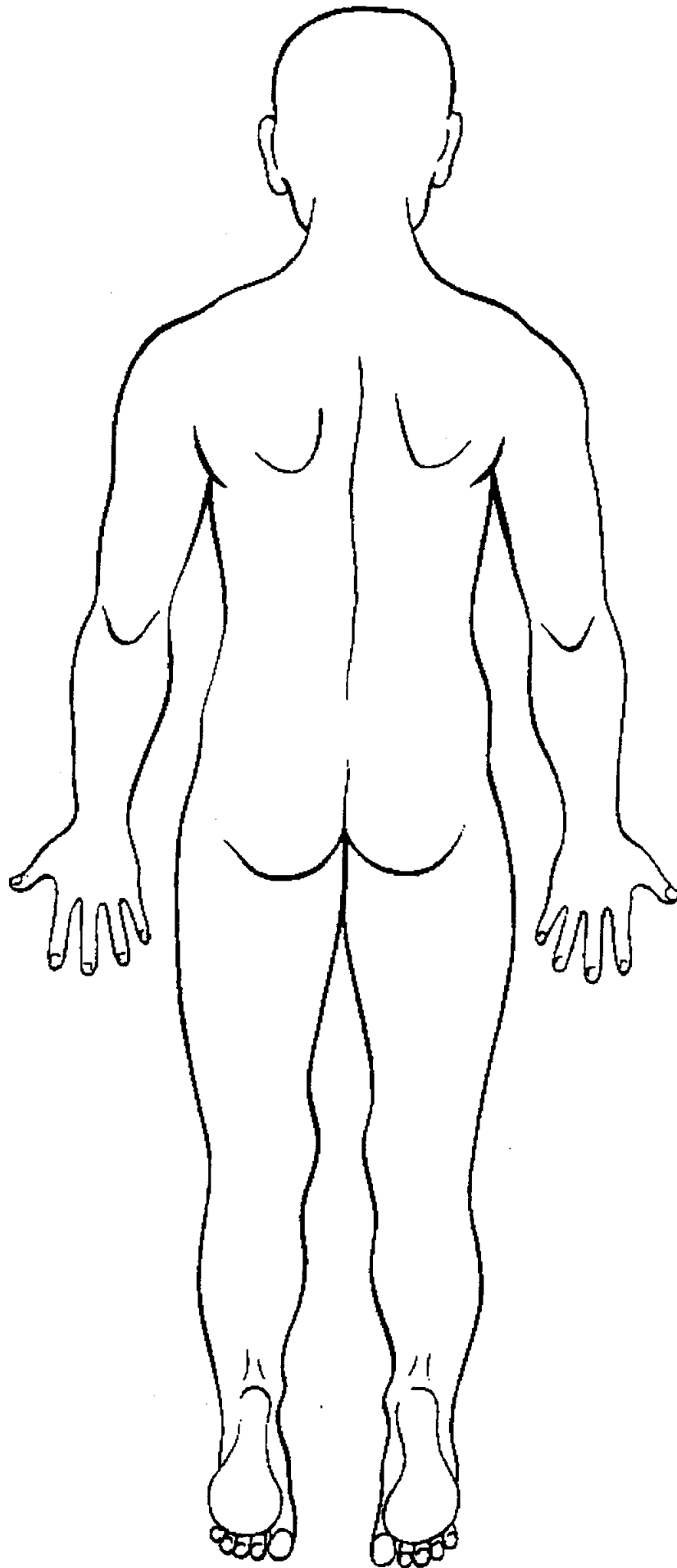
X 0045558



CASE NO:

NR 03
032 B

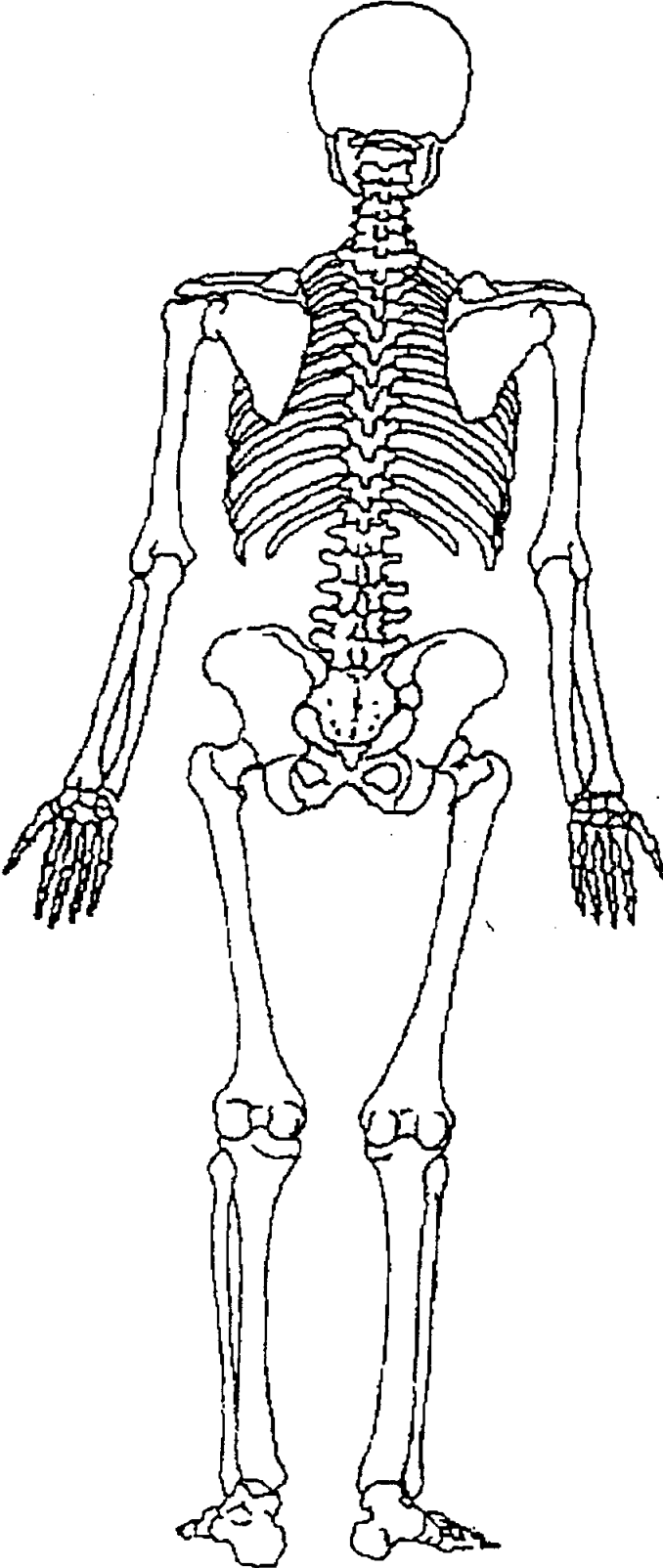
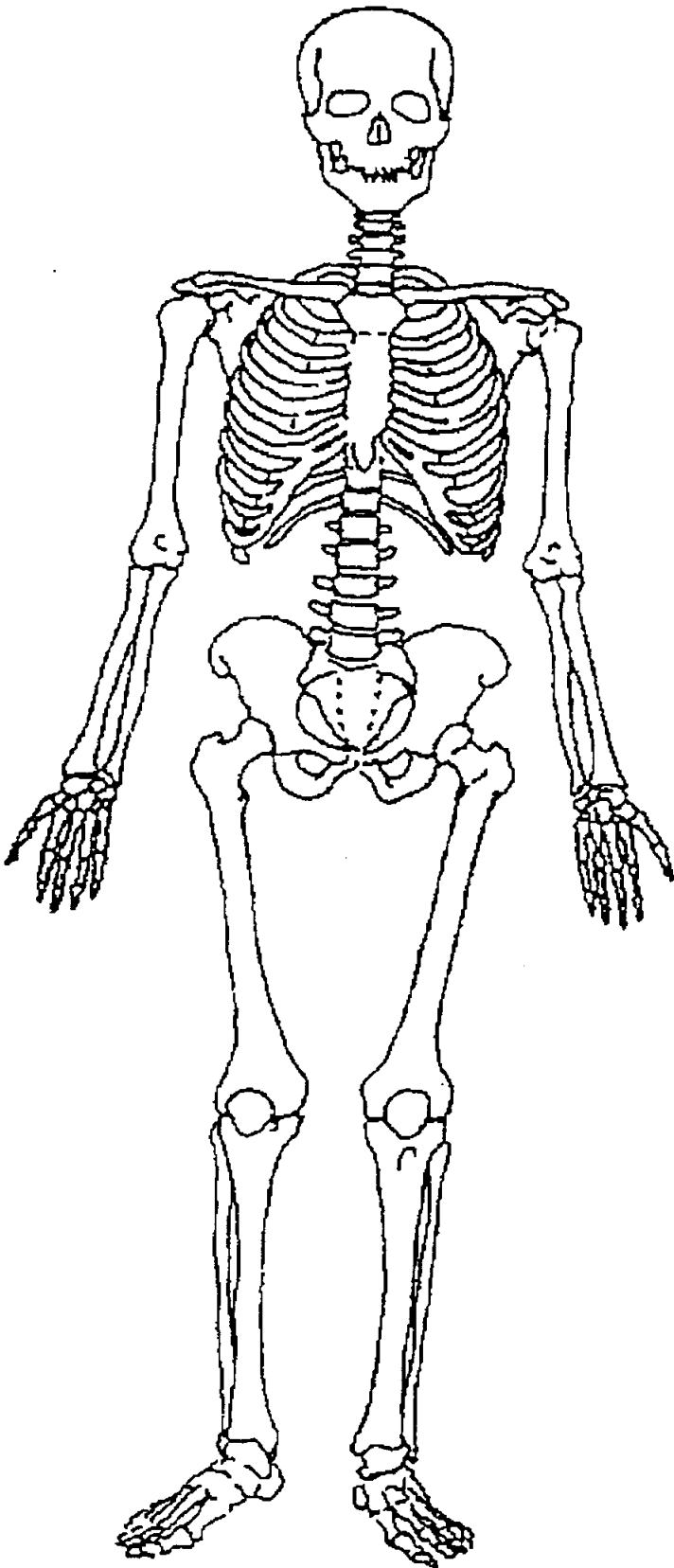
X 0345559



NK 04
032 B

CASE NO:

X 0045560



NK 04
032 B

CASE NO:

X 0045561

