



X0124298

United Nations International Criminal Tribunal for  
the former Yugoslavia

**AUTOPSY REPORT**  
RAVNICE GRAVE SITE

**Case No:** RV02 / 221B

**Autopsy Date:** 09-Aug-01

**Mortuary:** Visoko

**Summary:**

Fully skeletonized human remains of an adult with some clothing and other personal belongings. Most of the bones of the main skeleton with commingled bones of another skeleton were found. Anthropologically estimated sex is male, age is 35-55 years and the stature is 182.0+/- 7.7 cm.

The deceased has sustained several high velocity bullet injuries to the head, chest and the pelvic region. Even though no bullet holes found in the remaining skull bone, the fracture pattern is consistent with a high velocity bullet injury. There was a fracture of the right humerus, which appears to be a blunt force-type injury and whether it is ante-mortem or post-mortem cannot be determined. The deceased could have died instantaneously after receiving the fatal bullet injury to the head of which direction cannot be determined.

**Cause of Death:**

It is my determination that the cause of death in case number **RV02 / 221B** was:

**High velocity penetrating bullet injury to the head.**

This formal report is based upon the autopsy report that I prepared at the time of my examination. Both reports truly and accurately reflect my findings.

Signed:  .....

**Dr A. Samarasekera, MD, MBBS, DLM, DMJ, Dip.FM**

**Date: 13-Aug-01**

**A. General Description of Remains:**

Fully skeletonized human remains of an adult with some clothing and personal belongings. All bones are dry and some of them were found within the clothes. There was a large part of a skeleton of one individual and some commingled bones of another were found. The commingled bones were separated from the main skeleton and taken into a separate bag.

**B. Clothing and Other Items:**

**Clothing:**

1. Trouser with a belt . Torn
2. Some torn scraps of clothes
3. A pair of socks
4. Elastic band
5. Underpants

**Blindfolds:** No

**Ligatures:** No

**Other Items:**

1. Small silver colour container.
2. Broken piece of a small mirror in a plastic case (red), plastic pendant -like structure.
3. A key
4. Two beaded chains.
5. A razor and two razor blades.

**C. Identifying Features:****Sex**

**From examination of soft tissues:** Not possible

**From anthropology details:** Male

**Age Range**

**From anthropology data:** 35 - 55 years

**Build** Not possible

**Height (cm)**

**From estimation of intact body:** Not possible

**From anthropology data:** 182.0+/-7.7 cm

**Hair**

**Head hair:** Not possible

**Beard:** Not possible

**Moustache:** Not possible

**Teeth**

**General description:** Some teeth in-situ in the broken jaw.

**Tattoos:** Not possible

**Scars:** Not possible

**Other Features:** None

**D. Body Parts Missing:** See Anthropology Report Anthropologist L. Leppo

**E. Injuries:****Findings on fluoroscopy**

Radiographer E. Canniff

- Opacity in the image (? Object).

**Main injuries described**

**Head & Neck**

- |   |  | Probably<br>ante-mortem             | Probably<br>post-mortem  | Cannot<br>tell           |
|---|--|-------------------------------------|--------------------------|--------------------------|
| 1 | Burst-out type fracture of the skull. The vault and the base are fractured into several small and large pieces. The mandible is also fractured from its body from both sides and the front portion is missing. Upon reconstruction of the skull large areas of bone deficiency in the facial, frontal, parietal and the base of the skull were noted. No bullet holes were found. Fracture pattern is consistent with high velocity bullet-injury. | <input checked="" type="checkbox"/> | <input type="checkbox"/> | <input type="checkbox"/> |

**Trunk**

- |   |   | Probably<br>ante-mortem             | Probably<br>post-mortem  | Cannot<br>tell           |
|---|---|-------------------------------------|--------------------------|--------------------------|
| 2 | Fracture of the pelvic bone. Iliac crest and the articular surface of left iliac bone are fractured with loss of bone tissue in a 2 x 3 cm wide area. Corresponding area in the sacrum is also fractured. The iliac bone is fractured into three separate pieces due to two linear fractures extending to the crest across the bone vertically. The ischial bone is also fractured but fracture fragments are intact. Upon reconstruction an area of 3 x 2 cm bone deficiency consistent with high velocity bullet injury was found in relation to the articular surface. | <input checked="" type="checkbox"/> | <input type="checkbox"/> | <input type="checkbox"/> |

**Arms**

- |   |  | Probably<br>ante-mortem             | Probably<br>post-mortem  | Cannot<br>tell                      |
|---|--|-------------------------------------|--------------------------|-------------------------------------|
| 3 | Fracture of the shaft of right humerus in its lower third. The bone is separated into two. No bone deficient areas. The injury is consistent with blunt force type injury.               | <input type="checkbox"/>            | <input type="checkbox"/> | <input checked="" type="checkbox"/> |
| 4 | fracture of the shaft of right clavicle in its middle third with chipped-off bone fragment in the inner surface in 3 x 2 cm area. The fracture pattern is consistent with bullet injury. | <input checked="" type="checkbox"/> | <input type="checkbox"/> | <input type="checkbox"/>            |

**F. Internal Tissues:**

No remaining tissue

**G. Samples and Other Items Recovered:**

Soco J. McCartney

**Bullets / Shrapnel**

None

**Anthropology**

None

**DNA**

- right femur
- tooth (no. 35)

**Other**

None



United Nations  
International Criminal Tribunal  
for former Yugoslavia

CASE NO:

RV 02  
221 BGRAVE SITE: ~~VISKO~~ RV 02

MORTUARY: 221 B

DATE: 09/08/2001

PATHOLOGIST: SM

ANTHROPOLOGIST: LL

## AUTOPSY REPORT

### A. GENERAL DESCRIPTION OF REMAINS (to include state of preservation)

Fully skeletonized human remains of an adult with some clothing and personal belongings. All bones are dry and some <sup>of them</sup> ~~bones~~ were found within the clothes. There was a large part of a skeleton of an individual and some commingled bones. The ~~bones~~ commingled bones were separated from the main skeleton and taken into a separate bag bearing number RV02 BP.

### Summary comment on preservation

- largely or totally skeletonized
- well preserved, perhaps with skin still present
- degree of preservation somewhere between these two

CASE NO: RVO2  
221B

**B. CLOTHING AND OTHER ITEMS**

Clothing (general description after washing)

Women with a salt & terry  
Some terry stripes of cloths  
A pair of socks.  
Elastic band.  
Under pant.

**Blindfold**

yes  no

Exhibit no.

Description and where placed

**Ligature**

yes  no

Exhibit no.

Description and where placed

**Other items and personal possessions**

- ~~Broken pieces of a small mirror in a plastic case (red)~~ Small silver colour container
- Broken pieces of a small mirror in a plastic case (red)
- Plastic, pendant like structure.
- A key
- Two beaded chains
- ~~Plastic~~ A razor and two razor blades.

**C. IDENTIFYING FEATURES**

**Sex** (from external examination) M  F  not possible

**Height** (only with intact body) ... *not possible* cms

**Build** heavy  average  thin  not possible

**Head hair** dark  light  grey  balding  not possible

comments .....

**Beard** yes  no  not possible  comments .....

**Moustache** (alone) yes  no  not possible

**Teeth** (general comment only- charting done elsewhere)  
..... *some teeth in situ in the broken jaw* .....

**Tattoos** yes  no  not possible

if yes, site and general description .....

**Scars** yes  no  not possible

if yes, site and nature .....

**Any other features to assist identification** ( for example, old injuries)

..... *Nil* .....

**D. ANTHROPOLOGY DETAILS and BODY PARTS PRESENT/ MISSING**  
( for completion by anthropologists on forms at end of report )



Main injuries (continued)

Trunk

Probably ante mortem	Probably post mortem	Can't tell
----------------------	----------------------	------------

② Fracture of the pelvic bone. ~~left~~  
 Ilic crest and the articular surface of  
 left ilic bone are fractured with  
 loss of bone tissue in 2x3 cm area.  
 Corresponding area in the Sacrum is  
 also fractured. The ilic bone is fractured  
 in to ~~two~~ <sup>three</sup> separate pieces due to two  
 linear fracture extending to the crest  
~~The injury is consistent with~~  
~~bullet entry wound~~ the bone vertically.  
 The ischial bone is also fractured  
 but fracture fragments are intact.  
~~The injuries are consistent with~~  
~~bullet injuries upon transitory~~  
 an area of ~~2x2~~ 3x2cm bone deficiency  
 consistent with high velocity ballist-  
 injury are found ~~inside~~ in relation to  
 the articular surface.





CASE NO: RV02  
221B

**G. SAMPLES AND OTHER ITEMS RETAINED**

(other than clothing, ligatures and possessions)

SOCO (initials) .....

(1) **Bullets / Shrapnel** (description and from where recovered )

Refers fluoroscopy

print number

.....	<input type="checkbox"/>
.....	<input type="checkbox"/>
.....	<input type="checkbox"/>
.....	<input type="checkbox"/>
.....	<input type="checkbox"/>
.....	<input type="checkbox"/>
.....	<input type="checkbox"/>
.....	<input type="checkbox"/>
.....	<input type="checkbox"/>
.....	<input type="checkbox"/>
.....	<input type="checkbox"/>
.....	<input type="checkbox"/>
.....	<input type="checkbox"/>
.....	<input type="checkbox"/>
.....	<input type="checkbox"/>
.....	<input type="checkbox"/>

(2) **Anthropology**

.....

.....

.....

.....

(3) **DNA**

R / femur

A tooth

.....

.....

.....

(4) **Other**

.....

.....

.....

.....

.....

.....

H. SUMMARY AND CONCLUSIONS

Fully skeletonized human remains of an adult. Even though several commingled bones were found ~~together with the main skeleton~~ most of the bones of the main skeleton <sup>were</sup> available with some clothing and personal belongings <sup>were</sup> found with skeletal remains.

Here

Fully skeletonized human remains of an adult with some clothing and other personal belongings. Most of the bones of the main skeleton with commingled bones of another skeleton were found. Anthropologically ~~estimated~~ ~~lead~~ ~~received~~ ~~several~~ ~~high~~ ~~estimated~~ sex is male, age is 35-55 yrs and no stature is 182.0 ± 7 cm.

The deceased had ~~received~~ <sup>sustained</sup> several high velocity bullet injuries to the head, chest and no pelvic region. Even though no bullet holes found in the vertex of skull bone, no fracture pattern is consistent with a high velocity bullet injury. There was a fracture of the ~~left~~ right humerus which appears to be a blunt force type injury and whether it is ante mortem or post mortem could not be determined. The deceased could have died instantaneously after receiving the fatal (continue on back of page as required)

CAUSE OF DEATH

bullet injury to the head of which the direction could not be determined.

It is my determination that the cause of death in case no. RV 02 221B was:

High velocity penetrating bullet injury to the head

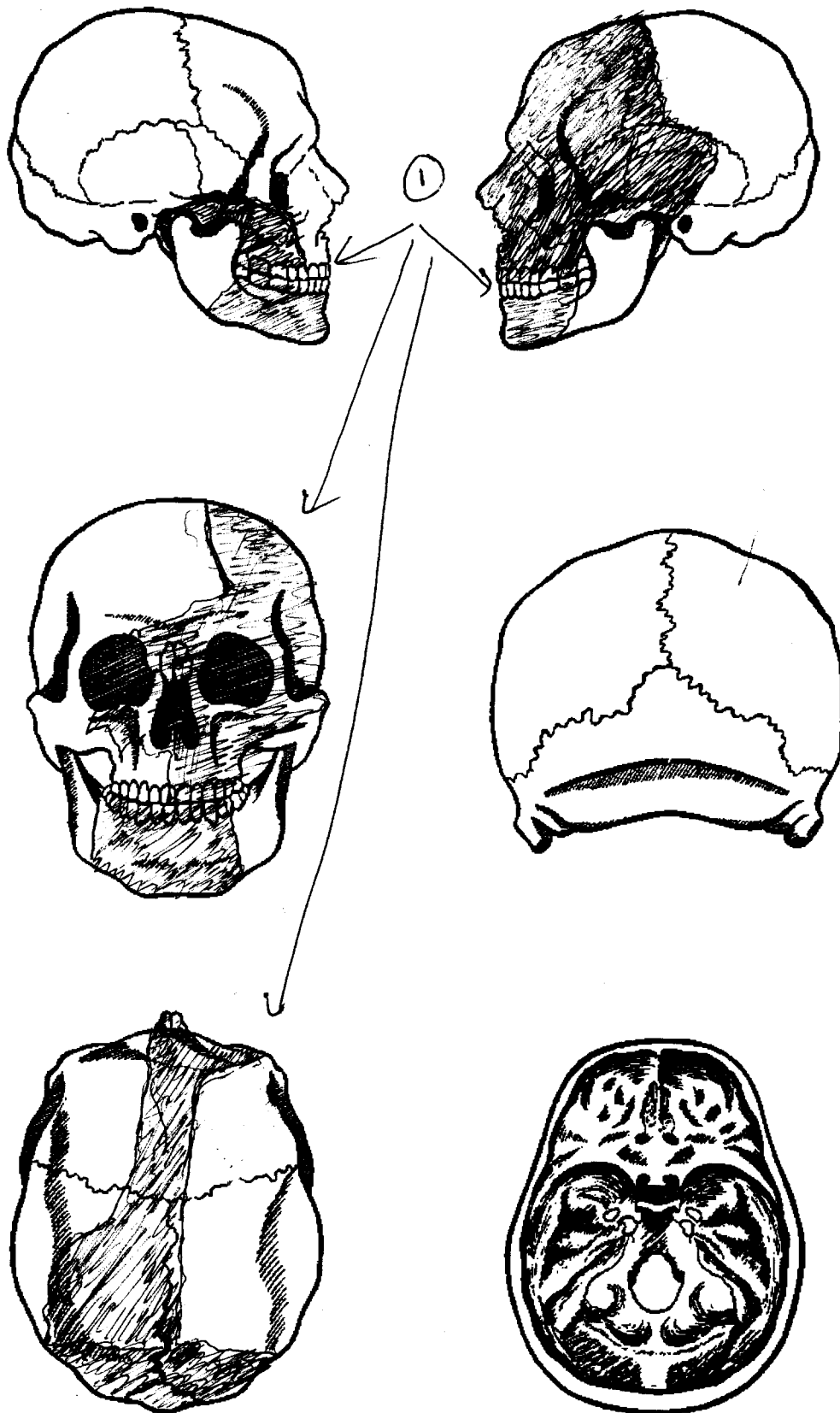
Signed: *[Signature]*


Name: Dr. Arundhan Saranathan

Qualifications (or title): M.D., M.D.S., D.M., D.S., D.F.P.S.

Date: 9/18/2001

CASE NO: RV 02  
221 B



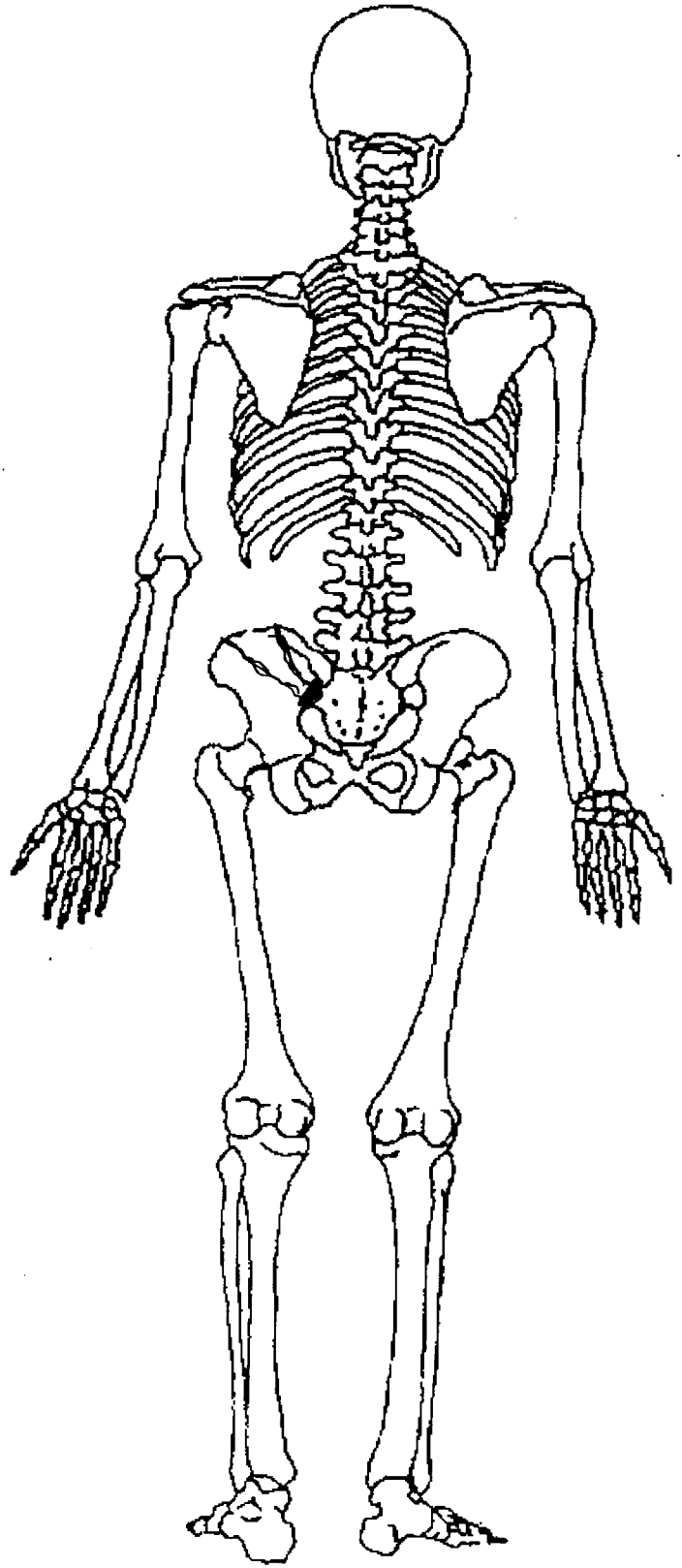
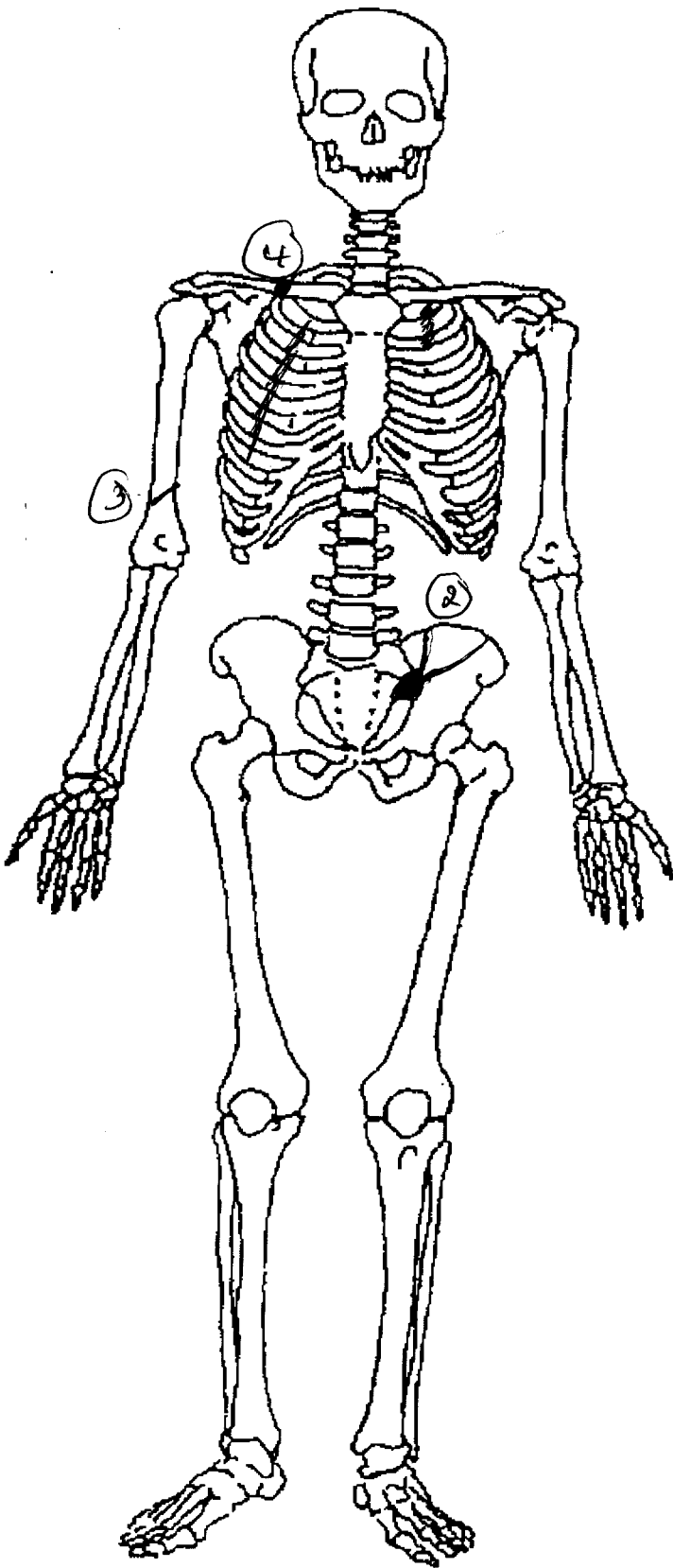
 Bone deficient area

X0124310

CASE NO:

RV 02

221 B



RV02  
221B

**ANTHROPOLOGY DETAILS** (to be completed by anthropologist) *JF*

(i) SEX: MALE/FEMALE/INDETERMINATE (circle one)

**Os coxae:**

Subpubic concavity ..... (1/0/NO)  
 Ischiopubic ramus ridge ..... (1/0/NO)  
 Greater Sciatic notch ..... (1/2/3/4/5/NO)  
 Ventral arc ..... (1/0/NO)  
 Preauricular sulcus ..... (1/2/3/4/NO)

**Cranium:**

Nuchal crest ..... (1/2/3/4/5/NO)  
 Mastoid process ..... (1/2/3/4/5/NO)  
 Supraorbital margin ..... (1/2/3/4/5/NO)  
 Prominence of Glabella ..... (1/2/3/4/5/NO)  
 Mental eminence ..... (1/2/3/4/5/NO)

(ii) AGE RANGE ..... 35 - 55 .....

	Side/Element	Phase	Range	Mean
Suchey-Brooks	<u>R</u>	<u>5</u>	<u>27-71</u>	<u>48.9</u>
Iscan-Loth	.....	.....	.....	.....
Lamendin	<u>33</u>	.....	<u>20.3-51.3</u>	.....

**Dental Calcification**

Tooth	Phase	Mean
.....	.....	.....
.....	.....	.....
.....	.....	.....
.....	.....	.....
.....	.....	.....
.....	.....	.....

**Union of Epiphyses**

Epiphyses	Fusion	Age
.....	.....	.....
.....	.....	.....
.....	.....	.....
.....	.....	.....
.....	.....	.....
.....	.....	.....

(iii) STATURE (cm) ..... 182.0 +/- 7.7 .....

Max Length Femur (R/L) ..... 502 .....

Other long bone (R/L) .....

(iv) ODONTOGRAM Yes No.....

RVO2  
221B

(v) SKELETAL INVENTORY (to be completed by anthropologist)

Please tick **ALL BOXES** (present or absent) and indicate (in #) the number of bones **PRESENT**.

Element	Present	Absent	#
CRANIUM			
Frontal	✓		
R Parietal	✓		
L Parietal	✓		
Occipital	✓		
R Temporal	✓		
L Temporal	✓		
R Maxilla	✓		
L Maxilla		✓	
MANDIBLE	✓		

Element	Present	Absent	#
R.Clavicle	✓		
L Clavicle	✓		
R Scapula	✓		
L Scapula	✓		
Manubrium	✓		
Sternal body	✓		
R Rib 1	✓		
L Rib 1	✓		
R Ribs	9		
L Ribs	11		

Element	Present	Absent	#
Atlas (C1)	✓		
Axis (C2)	✓		
C3-7	5		
T1-T12	12		
L1-L5	5		
R Os Coxa	✓		
L Os Coxa	✓		
Sacrum	✓		
Coccyx	✓		

RIGHT ARM	Present	Absent	#
Humerus	✓		
Radius	✓		
Ulna	✓		

LEFT ARM	Present	Absent	#
Humerus	✓		
Radius	✓		
Ulna	✓		

RIGHT HAND	Present	Absent	#
Carpals		✓	
Metacarpals		✓	
Phalanges		✓	

LEFT HAND	Present	Absent	#
Carpals		✓	
Metacarpals	1		
Phalanges		✓	

RIGHT LEG	Present	Absent	#
Femur	✓		
Patella	✓		
Tibia		✓	
Fibula		✓	

LEFT LEG	Present	Absent	#
Femur	✓		
Patella		✓	
Tibia	✓		
Fibula	✓		

RIGHT FOOT	Present	Absent	#
Calcaneus		✓	
Talus		✓	
Other tarsals		✓	
Metatarsals		✓	
Phalanges		✓	

LEFT FOOT	Present	Absent	#
Calcaneus		✓	
Talus		✓	
Other tarsals		✓	
Metatarsals		✓	
Phalanges		✓	

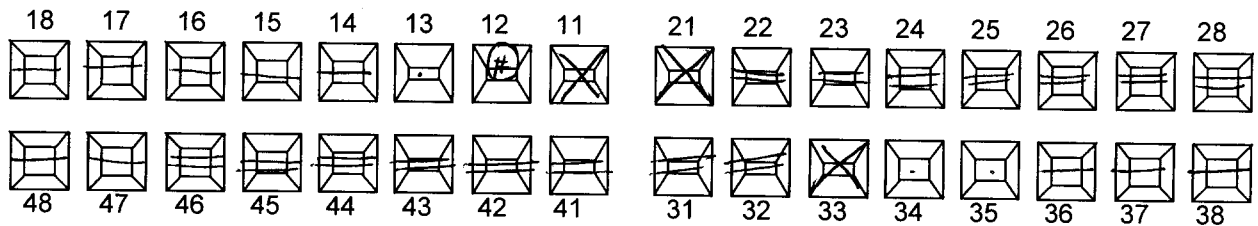
COMMENTS: Healed fracture of left first rib

Case No  
R102 / 221 B

**Odontogram**

**Dental Findings** in permanent teeth (notify temporary teeth specifically)

11	lpm	lpm	21
12	grossly carious root		22
13	sound		23
14	lam		24
15	lam		25
16	lam		26
17	lam		27
18	lam		28



48	lam	lam	38
47	lam	lam	37
46	not recovered	lam	36
45	not recovered	sound	35
44	not recovered	sound	34
43	not recovered	lpm	33
42	not recovered	not recovered	32
41	not recovered	not recovered	31

Specific Description Of Crowns, Bridges and Dentures	
Further Findings Occlusion, attrition, Anomalies, smoker, Periodontal status etc.	
X-rays taken of	
Supplementary Examination	
Estimated age	Method



**BODY RECOVERY REPORT.** Site: (code) RANDICE Body/(Body Part)No. RV-02-221-B  
(Complete in ink. Do not write on reverse. Initial errors)

Recorder: (Full Name) Pick Snow Time/Date: 20/07/01 1520

Body: Skeletonised - Partly Skeletonised - Saponified

Coordinates Surveyed ..... C.P. 59698 SECTOR E .....

Lies on:	Front	<u>Back</u>	Right Side	Left Side
Body:	<u>Extended</u>	Bent at hips	Tightly bent	
Left Arm:	Extended	Bent at elbow	<u>Tightly bent</u>	
Right Arm:	Extended	Bent at elbow	<u>Tightly bent</u>	
Left Leg:	<u>Extended</u>	Bent at knee	Tightly bent	
Right Leg:	<u>Extended</u>	Bent at knee	Tightly bent	

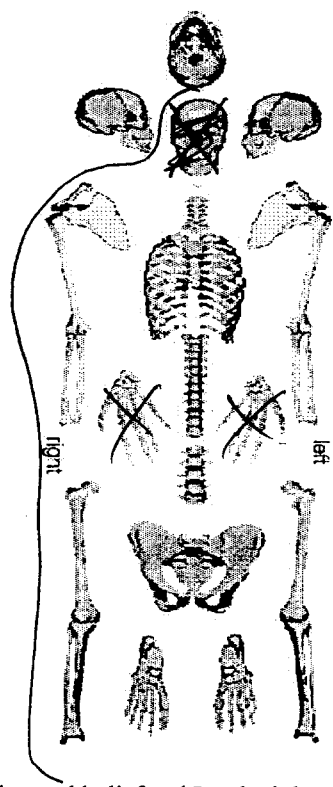
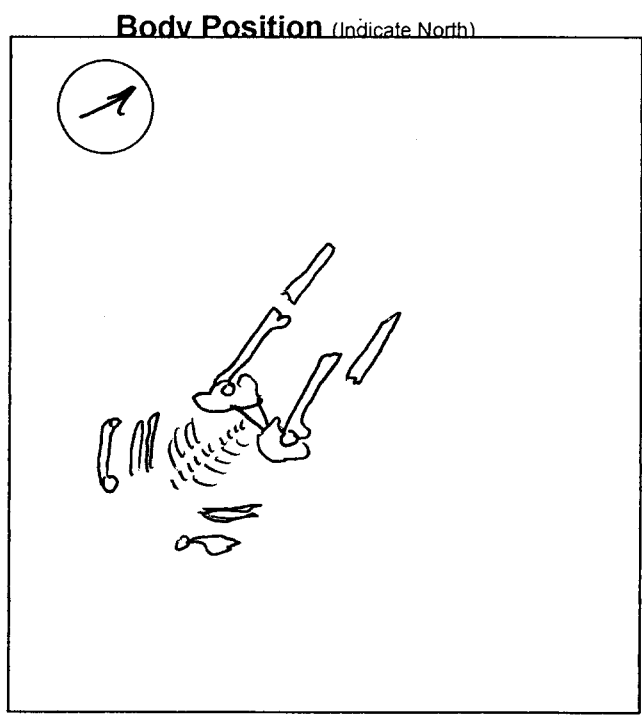
Clothing: (Using standard description list) GREEN NYLON JACKET

Artefacts associated to body: (i.e. Documents/Jewellery/Watch) Blindfold: Y (N) Ligature: Y (N)

BLUE PLASTIC RAZOR, YELLOW PLASTIC LIGHTER, 2 INJECTION VIALS,

Additional Information: (Factual observations and information to assist in determining cause of death or identification of victim)

SKULL BARELY FRACTURED



This statement, consisting of one page, is true to the best of my knowledge and belief and I make it knowing, that if it is tendered in evidence I shall be liable to prosecution if I have wilfully stated in it anything I know to be false or do not believe to be true.

Signed Pick Snow

Date 20/07/01

**IZVJESTAJ O PRONADJENOM TIJELU.** Lokacija: (naziv) RAVNICE Tijelo (Dio tijela) br. RV-02-221 B  
(Popuniti hemijskom olovkom, ne pisati na poledjini. Staviti inicijale pored ispravljene greske)

Bilježnik: (puno ime) RICK SNOW Time/Date: 20/07/01 1520

Tijelo: Skeletinizirano - Djelimicno skeletinizirano - Saponificirano

Koordinate CP 596-978 SEKTOR "E"

Lezi na:	prednjoj strani	<u>na leđjima</u>	Desna strana	Lijeva strana
Tijelo:	<u>ispruzeno</u>	savijeno u bokovima	jako savijeno	
Desna ruka:	ispruzena	savijena u laktu	<u>jako savijena</u>	
Desna ruka:	ispruzena	savijena u laktu	<u>jako savijena</u>	
Lijeva noga:	<u>ispruzena</u>	savijena u koljenu	jako savijena	
Desna noga:	ispruzena	savijena u koljenu	jako savijena	

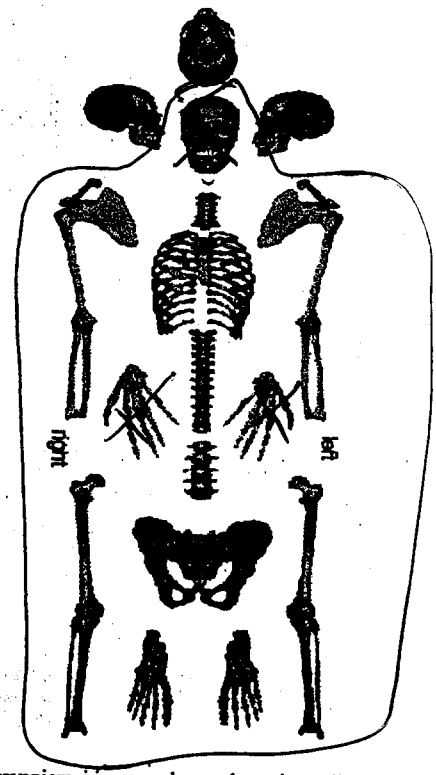

Odjeca: (koristiti standardnu listu kod opisa) ZELENA BALON JAKNA

Predmeti nadjeni uz tijelo: (npr. Dokumenti/nakit/sat) povez za oci: Da / Ne povez za ruke: Da / Ne

odatne informacije: (Cinjenicne observacije i informacije od pomoci za odredjivanje uzroka smrti ili identifikacije zrtve)

<u>JAKO POKOLJENA LORANJA</u>

**Položaj tijela** (naznaciti pravac sjevera)



Ova izjava koja se sastoji od 1 strane, je istinita, u skladu sa mojim najboljim znanjem i vjerovanjem, i ja znam da cu, ako se ista prilozi kao dokazni materijal, odgovarati za krivicno djelo ukoliko svojom voljom izjavim/navedem nesto sto je lazno ili nesto za sta ne vjerujem da je istina.

Potpis

Datum

preveo: Zvezdan Karadzic (MJH 2001)

# Surrogate Sheet

## PHOTOGRAPHS

Black & White

ERN: X012-4316- X012-4316

### SYNOPSIS / DESCRIPTION OF EVIDENCE

FLUROSCOPY IMAGES ATTACHED TO THE AUTOPSY REPORT OF THE  
BODY RV02/221B

Cross Reference ?

If Yes ERN