

ZJ05B 189

1. Photo ✓ Ron

NO033428

2. Log Checked ~Ton

3. X-ray

A handwritten signature in black ink, consisting of several loops and a long horizontal stroke extending to the right.

4. Path ✓

5. Anth ✓

6. 2nd Photo ✓



United Nations International Criminal Tribunal for the former Yugoslavia

ISOLATED BONE REPORT
ZJ05 GRAVE SITE

CASE NO: ZJ05B189 AUTOPSY DATE: 16.10.98 **χ0033429**
Sex determined by soft tissue: NOT ASCERTAINABLE
Height, by direct measurement: NOT ASCERTAINABLE
Body build: NOT ASCERTAINABLE

SUMMARY:

In my opinion the cause of death of ZJ05B189 was gunshot and shrapnel wounds to the chest, abdomen and pelvis.

Comment:

The partial body of an adult male aged 27-66 years of undetermined stature showing skeletonization and adipocere formation. No clothes were present. No ante-mortem injuries present. Post-mortem injuries were present to the left humerus, right ulna, ribs and distal ends of both humeri. The fluoroscopic examination showed abundant metal foreign bodies to the arms, thorax, abdomen and pelvis. Jacket metal was retrieved from the right side of the pelvis. Shrapnel fragments were recovered from the thoracic spine, abdominal area and pelvis; the largest piece (5 x 2 cm) was recovered from the abdomen. Also present was a spring within the flesh of the left hip area and a cylindrical piece of material with a spiral pattern on it in the same area. This is in keeping with the components of an anti-personnel device, possibly a grenade. Disruption of the lower lumbar spine, sacrum and pelvis were present.

I am of the opinion that this male has been shot in the pelvis and received shrapnel wounds to the thorax, abdomen and pelvis. Part of a grenade entered the pelvic tissue on the left side and the explosion has disrupted the pelvic bones. A fragment of clear glass was also found in the pelvis. This was cuboid in appearance and may have originated from a window or even a glass component of a vehicle.

This formal report is based upon the autopsy report that I prepared at the time of my examination, and both reports truly and accurately reflect my findings.

Signed:*G. Ruty*.....

Dr. G. Ruty, MB BS, MRCPath., Dip. RCPath. (Forensic).

Date: 16.10.98

CLOTHING: NO

PERSONAL EFFECTS: NONE

IDENTIFICATION PAPERS OR ID CARD: NONE

X0033430

BONES PRESENT (length and condition):

Left clavicle; left and right scapula; manubrium; left humerus (part); 3 right ribs; 10 left ribs; 25 fragments of ribs; right humerus; right ulna; 4 x lumbar vertebrae; 6 x thoracic vertebrae; pelvis x 2; sacrum; femora x 2.

COMMINGLING: NO

HEAD HAIR: N/A

Colour:

Length:

BEARD/MOUSTACHE/BODY HAIR: UNKNOWN

OLD INJURIES: NONE

IDENTIFYING CHARACTERISTICS: NONE

DENTAL STATE: N/A

TRAUMA RELATED TO DEATH:

No ante-mortem injuries.

There was disruption of the 4th/5th lumbar spine, sacrum (3 pieces) and left hemipelvis (3 pieces). The right inferior pubic ramus had a bone piece missing and with the body of the left hemipelvis there was a possible projectile with internal bevelling.

RECENT TRAUMA UNRELATED TO DEATH:

Left lower humerus; right lower ulna; ribs; both lower ends of femurs.

INTERNAL EXAMINATION: N/A

RECOVERED OBJECTS: YES

Projectiles:

ZJ05B189.1A and B -- All projectiles and fragments. The thorax, abdomen and pelvis contained a considerable number of metallic fragments including shrapnel, glass, a core and spring from a possible grenade and glass. These were recovered from the upper thoracic spine (shrapnel); left hip area (grenade core); lumbar spine (shrapnel); right pelvis (bullet jacket fragment); flesh of the left hip (spring); left of pelvis (metal); lower abdomen (shrapnel 5 x 2 cm); pelvis (glass) and lower abdomen (shrapnel, 3 x 2 cm).

Case No: ZJ05B189

Other objects:

ZJ05B189.2 -- Biological sample, left clavicle

HANDED TO: Ton Van Manson

BONE FLUOROSCOPED BY: Patrick Reynolds

X0033431

ISOLATED BONE REPORT



X0033432

CASE No.
2305
0199

United Nations International Criminal Tribunal for
former Yugoslavia

.....GRAVE-SITE, BOSNIA

ISOLATED BONE REPORT

AUTOPSY DATE: 6/10/98

AUTOPSY ROOM:

PATHOLOGIST: G. LUTY

EXTERNAL EXAMINATION

HEIGHT (SEE ANTHROPOLOGY REPORT): — Age 27-62

For summary see page 8

LIGATURE No

BLINDFOLD No

BANDAGE No

CLOTHING List as removed (Detail on special form)

No

Initials..... *GL*

ISOLATED BONE REPORT

CASE No.
2505
D181

X0033433

PERSONAL EFFECTS (handed to:)

Brief details (e.g., "wallet", no need to list contents which will be listed by evidence gatherers)

Item	Recovered from	Item	Recovered from
None			

IDENTIFICATION PAPERS OR ID CARDS None

BONES PRESENT (condition eg skeletonised)

- | | |
|------------------------|--------------|
| (L) clavicle | (R) humerus |
| (L) + (R) Scapulae | (R) ulna |
| Manubria | 4 x lumbar |
| (L) humerus - part | 6 x thoracic |
| (3) right ribs | pelvis x 2 |
| (10) left ribs | Sacrum |
| Fragments of ribs x 25 | femur x 2 |

COMMINGLING; Yes () No (✓)

If so, give details

OLD INJURIES: (SPECIFY SITE AND DETAILS) See also Anthropologist's Report

None

Initials.....*amb*.....

CASE No.
2505
D189

ANY OTHER IDENTIFYING CHARACTERISTICS:

None

Jaws retained for odontologist Yes() No(✓) (see notes)

TRAUMA RELATED TO DEATH (List and record on body diagrams)

Were any bones/skull reconstructed by anthropologist: Yes() No(✓)

If yes, which:

DESCRIPTION OF INJURIES (Please number)

~~1) Disruption of the 6th lumbar spine~~

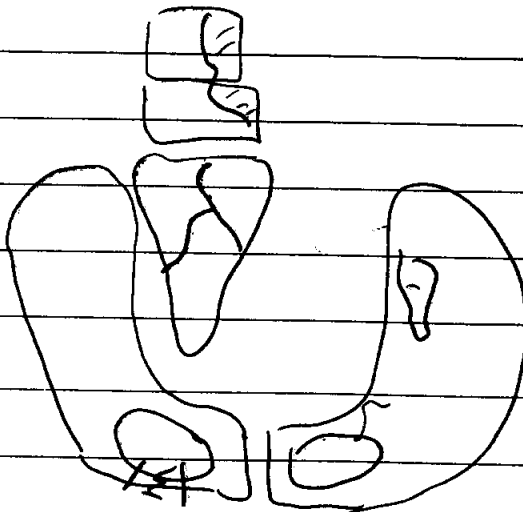
2)

No antemortem

~~No perimortem injuries~~

There was disruption of the 6th / 5th lumbar spine, Sacrum (2 pieces) and ① hemipelvis (3 pieces). The ② inferior pubic ramus had a bone piece missing and was the only of the ③ hemipelvis there was a ? possible injury

Subsides is intense



Initials..... AMB

RECENT TRAUMA UNRELATED TO DEATH (i.e. POSTMORTEM)

(C) Lower humerus	left	} left post mortem trauma
(N) lower ulna	right	
ribs	both lower ribs frags	
left hand		

RECOVERED OBJECTS:

PROJECTILES

Was the body fluoroscoped Yes (✓) No () Name of Radiographer:

Number of bullets seen on fluoroscopy: Number found:

Position of bullets, complete, jacket, core, small /medium or large calibre, full jacket

1. All placed on one paper given as ZJOS B189-1A and B
2. ~~missile~~ (C) clavicle B189-2
- 3.

OTHER OBJECTS:

Handed to:

The thorax, abdomen and pelvis contained a considerable number of metal fragments including shrapnel, glass, a core and springs from a ? grenade and glass. These were recovered from

- 1) shrapnel - upper thoracic spine
- 2) grenade grenade core hip area (C)
- 3) shrapnel - lumbar spine (
- 4) bullet jacket fragment (N) pelvis
- 5) bullet jacket fragment (N) pelvis
- 6) springs in flesh (C) hip
- 7) metal (C) of pelvis

handed to
TON

Initials..... ch.....

- (P) shrapnel lower abdomen (5x2cm)
- (7) glass pelvis - cuboid clear glass
- (10) lower abdomen shrapnel (3x2cm)

CASE No.
2505
5189

SUMMARY

The partial body of an adult male age 27-66 of undetermined stature showing skeletal maturation and adipose formation. No clothes were present. No antemortem injuries present. Postmortem injuries present to the (L) humerus, (R) ulna and distal ends of both humeri.

The humeri showed advanced metal foreign bodies to the arms, thorax, abdomen and pelvis. Jacket metal was retrieved from the right side of the pelvis. Shrapnel fragments were recovered from the thoracic spine, tallobrail area and pelvis, the largest piece (5x2cm) was retrieved from the abdomen. Also present was a spring.

It is my determination that the death of was caused by: PTD

Gunshot and shrapnel wounds to the chest, abdomen and pelvis

.....and I so certify.

Signed Calog Qualifications M.D.S. Date 16/10/97
MRCRAN
D.P. R.C.R.A. (Forensic)

Initials Calog

within the flesh of the (C) hip area and the pattern cover of
a garment in the same area. Disruption of the lower lumbar spine,
Sacrum and Pelvis was present.

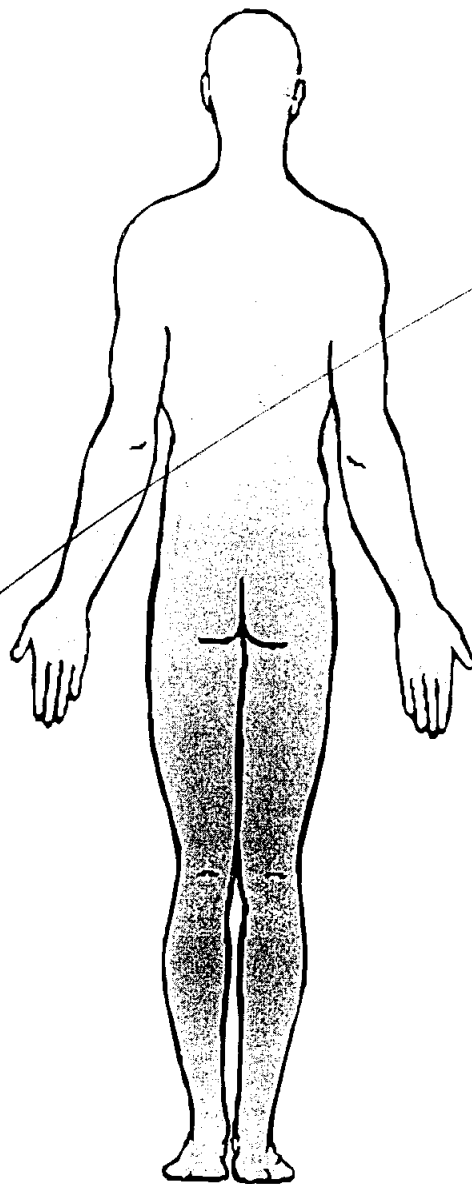
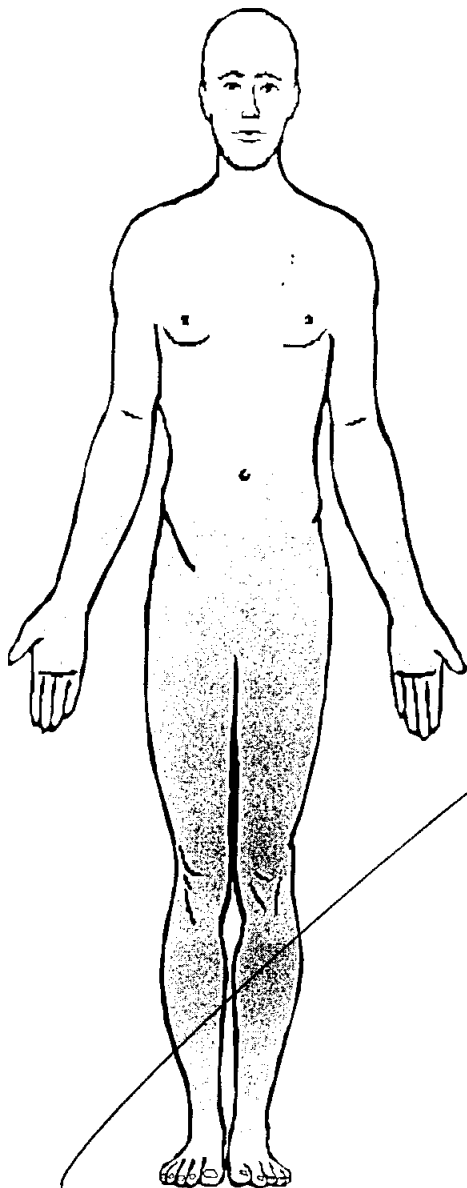
I am of the opinion that the male has been shot in the pelvis and
received shrapnel wounds to the thorax, abdomen and pelvis. Part of
a garment has entered the pelvic tissue on the left side ^{and} the
explorer has disrupted the lowest pelvic bones. Fracture a fragment of
bones was also found in the pelvis.

ISOLATED BONE REPORT

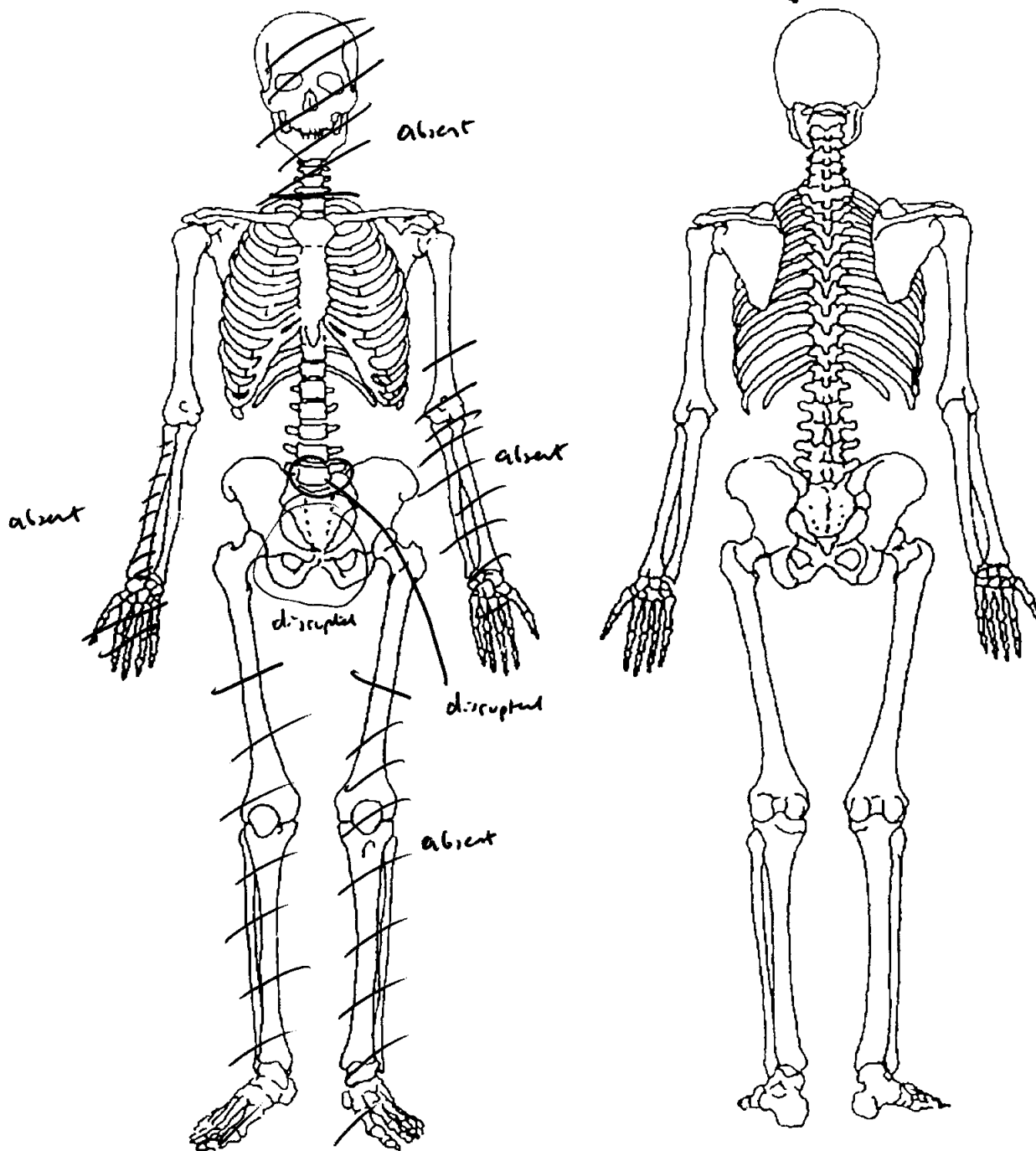
00033438

X0033438

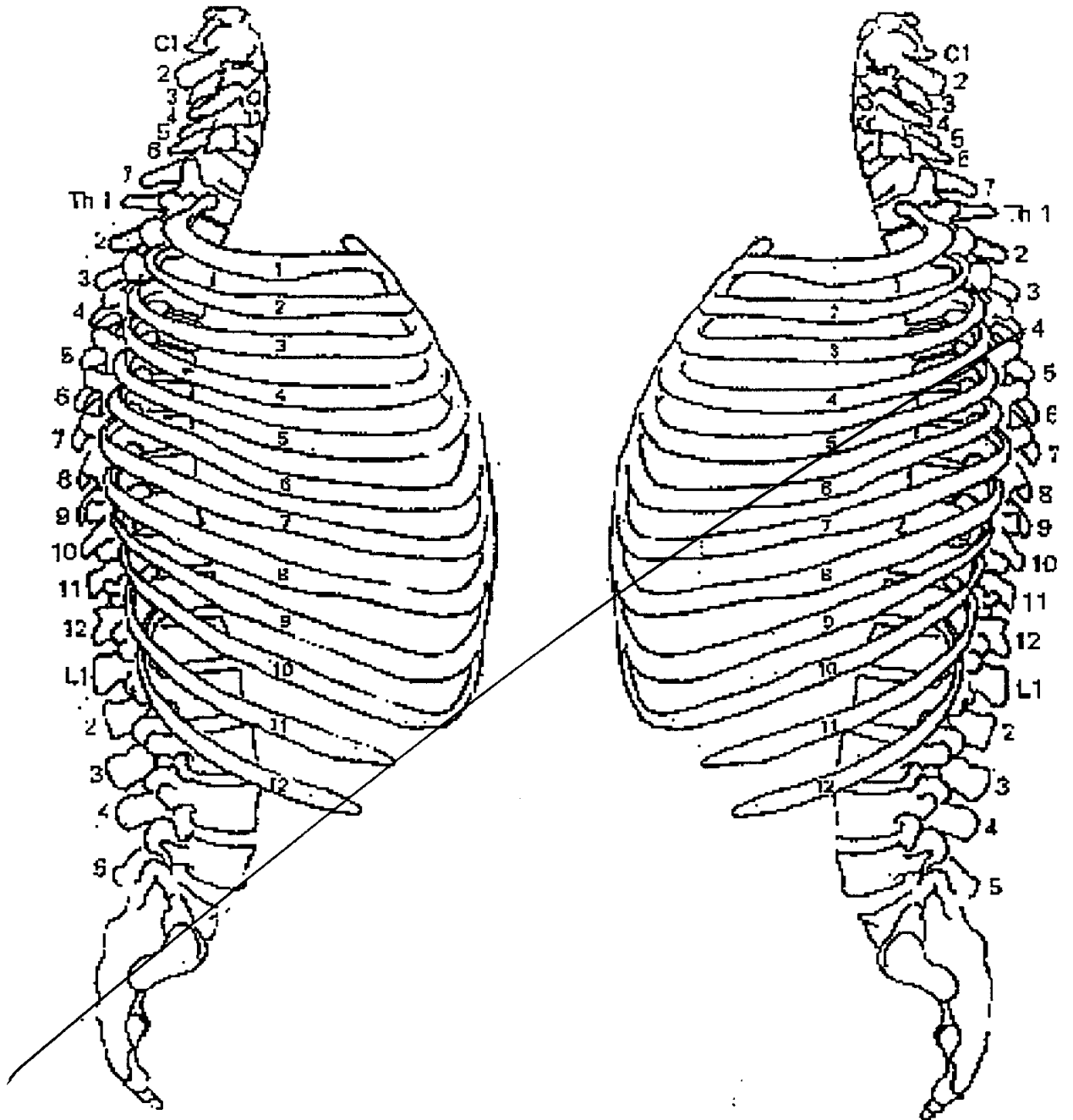
CASE No.
250.
0189



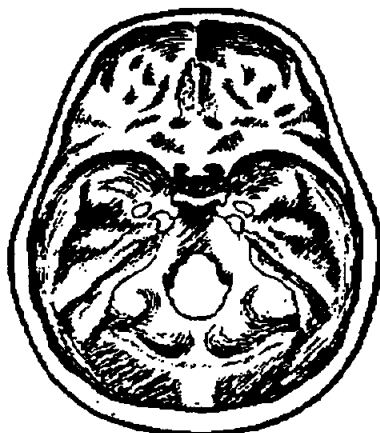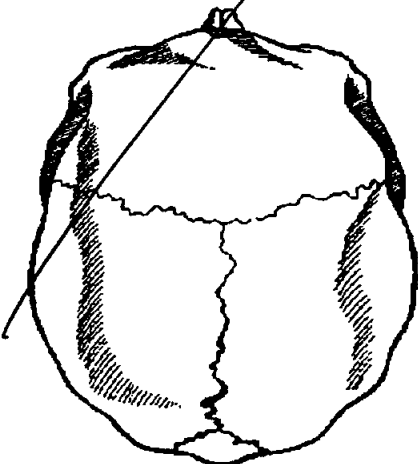
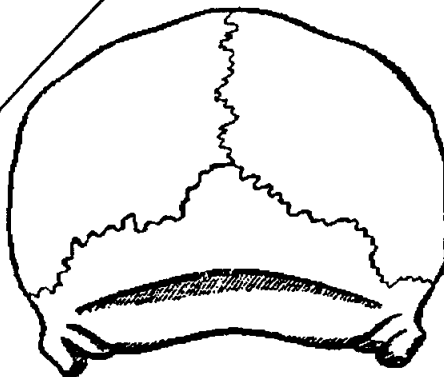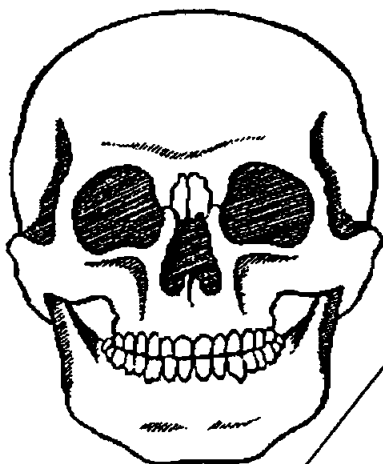
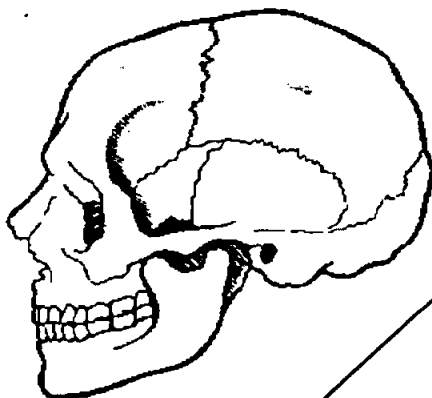
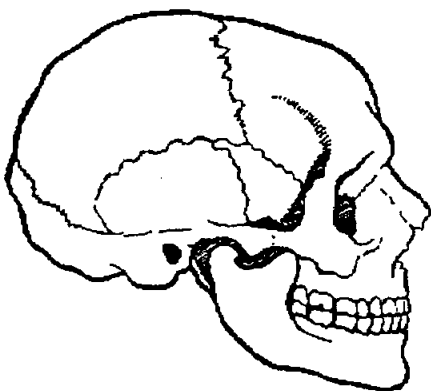
Initials.....*cmh*.....



Initials..... *CH*



Initials... *CMY*



Initials... *CDW*

X0033442



United Nations International Criminal Tribunal for the former Yugoslavia

Z505 GRAVE-SITE, BOSNIA

ANTHROPOLOGY FORM

Body # B189 Date 10/10/98

Anthropologist A.L. SCHILING

Pathologist G. RUTTY

SEX MALE FEMALE / INDETERMINATE (circle one)

Os coxae:

Subpubic concavity (1) NO
Ischiopubic ramus ridge (1) NO
Greater Sciatic notch (1/2/3/4) NO
Ventral arc (1) NO
Preauricular sulcus (1/2/3/4) NO

Cranium:

Nuchal crest (1/2/3/4/5) NO
Mastoid process (1/2/3/4/5) NO
Supraorbital margin (1/2/3/4/5) NO
Prominence of Glabella (1/2/3/4/5) NO
Mental eminence (1/2/3/4/5) NO

L

AGE RANGE ADULTS 27-66

Table with columns: Suchey-Brooks L, Phase, Range, Mean. Values: 5, 27-66, 45.6. Iscan-Loth: ABSENT

AGE RANGE SUBADULTS

Table with columns: Dental Calcification Tooth, Phase, Union of Epiphyses Epiphyses, Fusion. Handwritten note: all fused

STATURE (cm)
Max Length Femur (R/L)
Max Length Tibia (R/L)
Max Length Fibula (R/L)
Other long bone (R/L)
Formula Used

BIOLOGICAL SAMPLES: CLAVICLE, MID-SHAFT